



Inguinal, or Hexsel's Hyperhidrosis

DÓRIS MARIA HEXSEL, MD
TACIANA DAL'FORNO, MD
CAMILE LUIZA HEXSEL

Abstract. *Inguinal Hyperhidrosis (IH) is a focal and primary form of hyperhidrosis in which the individual has intense sweating in the inguinal region. It usually appears in adolescence, not later than the age of 25, in the most cases, and continues into adulthood. With a sample of 26 patients we described Inguinal Hyperhidrosis (IH). Fifty percent of the patients have a positive family history of this condition or other forms of focal or generalized hyperhidrosis, which suggests a familial pattern. Biopsies performed on the inguinal area in a patient with IH and control patient showed normal histology. Excessive perspiration in the inguinal area significantly affects the quality of life of the patients. It is an embarrassing condition that produces large wet stains on the clothes, therefore making daily activities difficult and compromising the emotional, professional and social life of the affected patients. The therapies commonly used for other forms of focal hyperhidrosis are not yet referred in the literature specifically for IH. Intradermal injections from botulinum toxin provide positive results for the patients and controls the sweating for 6 months or more. It is a simple, safe and effective treatment for this condition and the results significantly improve the quality of life of the affected individuals.*

Hyperhidrosis is characterized not merely by excessive sweating but also by any amount of sweating that causes physical, emotional, and/or social discomfort for the patient.¹ Generalized hyperhidrosis is usually due to a systemic cause.² Focal forms of hyperhidrosis may be restricted to one anatomic area but can occur in more than one area of the body. Inguinal hyperhidrosis, or Hexsel's hyperhidrosis (HH), is a focal hyperhidrosis in which the individual has intense sweating in the crotch area. It is a primary form of hyperhidrosis and is often associated with other forms of hyperhidrosis.³

Clinical Characteristics

HH is characterized by chronic, intense sweating in the inguinal region and is made evident by wet clothes, a situation that is quite embarrassing for the patient. HH symmetrically affects the groin region, including the suprapubic area, the shallow depression that lies immediately below the fold of the groin (corresponding to the femoral triangle), the medial surfaces of the upper inner thighs, and the genital area. It may also include the lower part of the gluteus maximus, gluteal fold, and natal cleft.

As with axillary hyperhidrosis,⁴ HH usually appears in puberty, generally before 25 years; it continues into adulthood and does not regress spontaneously. With

the advance of age, HH may diminish in intensity, as often occurs with other forms of focal hyperhidrosis.⁴ Both sexes are affected, although as yet there is no epidemiologic comparison available. Fifty percent of the patients with HH have a positive familiar history of HH or other forms of focal hyperhidrosis. This suggests an inheritance pattern.

HH seems not to be a highly prevalent condition, appearing with less frequency than other forms of focal hyperhidrosis, such as that occurring on the axilla, the palms, and the soles. Awareness of this condition is important because some forms of focal hyperhidrosis are often associated with other forms of focal or generalized hyperhidrosis, and this association is not usually investigated. On the other hand, HH is not a widely reported complaint because most sufferers are unaware of the possibility of treatment for this condition. It may be the case that the prevalence of the condition would be significant if it were investigated more thoroughly. The description of inguinal hyperhidrosis given in this article is based on a sample of 26 individuals presenting with this disorder.

Etiology

The cause of HH is unknown. The sweat glands and their innervation do not show any histologic abnormalities. There may be dysfunction of the central sympathetic nervous system, possibly of the hypothalamic nuclei, the prefrontal areas, or their connections. Sufferers display no other signs or symptoms of autonomic dysfunction.⁵ HH may occur as an isolated manifestation of focal hyperhidrosis, but it is more commonly associated with other forms of focal hyperhidrosis, such as that of the axilla, palms and/or soles, cervical region,

From the Department of Cosmetic Dermatology, Brazilian Society of Dermatology, Porto Alegre, Brazil; the Department of Dermatology, School of Medical Sciences, Federal University of Rio Grande do Sul, Porto Alegre, Brazil; and the School of Medicine, University of Passo Fundo, Brazil Passo Fundo, Brazil.

Address reprint requests to: Dóris Maria Hexsel, MD, Plínio Brasil Milano, 476-Zip 90520-000, Porto Alegre RS, Brazil.

E-mail address: dohexsel@zaz.com.br

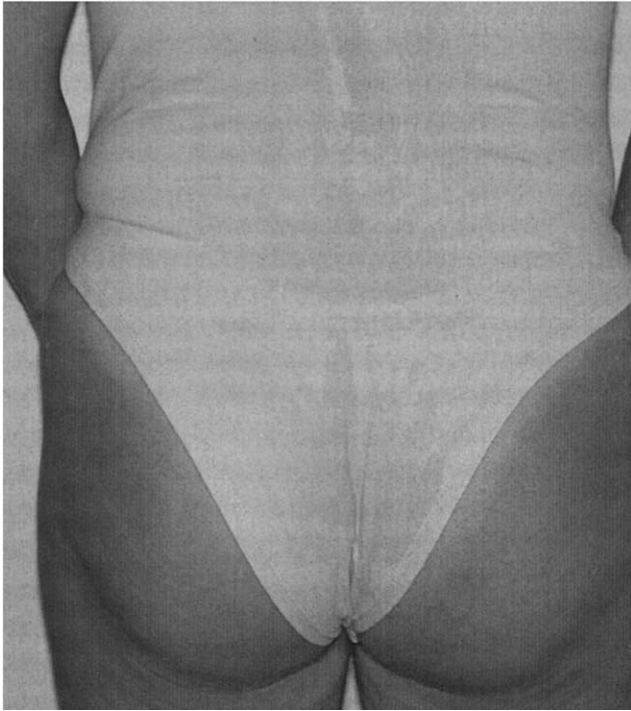


Figure 1. Wet clotting on an HH patient also showing sweating on the back.

and less frequently, the back, face, and chest (Fig 1). Of these, it is most commonly found in association with axillary hyperhidrosis and generalized hyperhidrosis. There is no relationship with the use of drugs or with metabolic, endocrine, or other diseases. Generalized hyperhidrosis is associated with these conditions.²

Sweat Glands in the Inguinal Region

There are three types of sweat glands present in the skin of normal axilla: eccrine, apocrine, and apoecrine.⁴ The same three types are found in the inguinal and genital area.⁶ As yet, the exact proportion of each of these gland types in the inguinal region has not been established.

Eccrine glands are present everywhere in human skin, including the inguinal region. They are absent, however, in areas of modified skin that lack all cutaneous appendages, ie, the vermilion border of the lips, nail beds, labia minora, the glans of the penis, and the inner aspect of the prepuce.⁷ These glands are most numerous on the palms, soles, face, axilla, and, to a lesser extent, the back and chest.² There is no relationship between the density of eccrine glands in normal individuals and the density of eccrine glands in those who suffer from focal hyperhidrosis.⁴ The number varies greatly with site, from 620/cm² on the soles to about 120/cm² on the thighs. These glands also vary in size from person to person.⁸

Apocrine glands are encountered in only a few areas: the axilla, anogenital region, and (as modified glands)

other regions of the body (eg, ceruminous glands, Moll's glands, and mammary glands). Occasionally a few apocrine glands are found on the face, in the scalp, and on the abdomen. As yet, the presence, distribution, and activity of the apocrine glands in the inguinal region have not been established. Because apocrine glands are not involved in thermoregulatory or salt-recovery processes, they are more briefly described in the literature. The function of apocrine glands in humans is not clear, although it is thought that they may be important for body odor and pheromones.⁴ Apocrine sweat is produced in small quantities and has very little, if any, role to play in hyperhidrosis.² Sweat gland density varies according to anatomic region. For example, in the normal axillary region, apocrine glands outnumber eccrine glands by approximately 10 to 1.⁶

More recently, a third type of gland, also found in the axillary and inguinal regions, has been described by Sato et al⁹ and termed "apoecrine," because they contain morphological features common to the other two types.⁶ The name was suggested because of the similarity to both human apocrine and eccrine glands. They are variable in size, and their ducts are similar to those of the eccrine glands on the skin surface. They apparently develop after adolescence in both sexes.⁶ These glands produce copious, watery fluid and may account for 10-45% of adult axillary glands.⁸

The degree to which each gland type is involved in axillary hyperhidrosis is unknown, but axillary sweat is believed to be of eccrine origin because of its profuse nature and watery consistency.⁴ This is also true of the inguinal region, where the same question remains. This fact, however, does not exclude the possibility that other glands may be involved.⁴

Sweat Gland Innervation and the Trigger for Sweating

The eccrine glands have a rich blood supply² and are innervated by cholinergic nerve fibers arising from the sympathetic nervous system, in contrast to almost all other sympathetic fibers, which are adrenergic.^{2,10} These glands are stimulated primarily by centers in the hypothalamus that are usually considered to be parasympathetic centers.¹⁰ Therefore, sweating could be called a parasympathetic function, even though it is controlled by nerve fibers that, anatomically, are distributed through the sympathetic nervous system.¹⁰

The innervation of the apocrine glands is poorly understood, and it is not known whether the apocrine gland is under direct neural control or humoral control.⁴ Under experimental conditions, the apocrine gland is equally responsive to both adrenergic and cholinergic stimuli. It is slightly more responsive to adrenaline than noradrenaline, suggesting that circulating hormone from the adrenal gland may be more

relevant than adrenergic stimulation from nerve terminals in the vicinity of the apocrine gland.⁴ The innervation of the apoeccrine gland is similar to that of the eccrine gland, but the secretory rate is approximately 10 times higher.¹¹

Stimulation of the anterior hypothalamus either electrically or by excess heat causes sweating.¹² When the sweat glands are stimulated only slightly, the secretion is released slowly. When the sweat glands are strongly stimulated by the sympathetic nervous system, however, sweat is released very rapidly.¹² The sweat glands produce a watery secretion important in thermoregulation.⁴ The production of sweat is continuous, but the *rate* of production is highly variable between and within individuals, depending on environmental stimuli such as temperature, exercise, or emotional stress.⁴ Emotional sweating can be induced by anxiety, embarrassment, fear, anger, excitement, or mental stress.² Local heating increases the local sweat gland response to reflex stimulation or acetylcholine, but intense local heating can elicit sweating directly, even in sympathectomized skin.² Exercise increases heat production, causing an increase in core temperature, which in turn elicits the sweating response.²

In general, the eccrine sweat glands in the palms and soles respond well to emotional stimuli, and those in the axilla and forehead respond to both thermal and emotional stimuli, whereas those in the rest of the body respond almost entirely to thermal stimuli.² It is well known that sweat induced by heat requires an intact autonomous sympathetic nervous system, whereas that induced by exercise also involves activation of the adrenal medulla catecholamines. This indicates the presence of a two-component sudomotor control system.⁶ In addition, although eccrine glands are involved in thermoregulation, this is not the case with apocrine glands in humans.¹²

Histology

The eccrine sweat glands consist of a secretory coil in the lower dermis and subcutaneous tissue and a duct leading through the dermis to the intraepidermal sweat duct unit. They open onto the surface.⁸ Apocrine sweat glands include a large, coiled, secretory portion and a relatively straight duct, which opens into the hair follicle canal near the surface of the skin. The ultrastructure of human apocrine glands is fundamentally similar to that of eccrine glands: an inner secretory epithelium, an outer myoepithelium, and a circumscribing fibrocyte sheath. The main structural difference is in the secretory epithelium, which in the apocrine gland is composed of a single layer of either cuboidal and/or columnar cells with nuclei located in the inferior portion of the cell.⁶ Apoeccrine glands have features of both eccrine and apocrine glands but seem to be closer to eccrine in

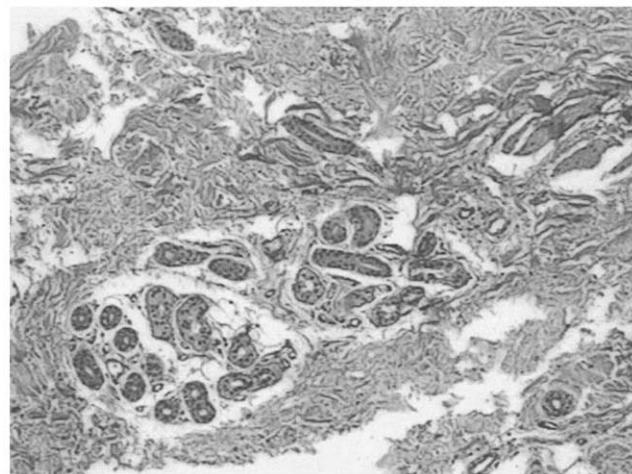


Figure 2. Histologic findings of inguinal region from an HH patient.

function.⁸ The secretory coil of an apoeccrine gland is similar to the apocrine secretory coil. The duct of an apoeccrine gland, however, connects directly to the skin surface, as is the case with eccrine glands.⁴

A study of the ultrastructure of hyperhidrotic eccrine sweat glands biopsied from the axilla and neck of individuals with primary hyperhidrosis showed the absence of structural defects in the glands.¹ The results reveal that the eccrine glands of hyperhidrotic individuals exhibit the morphological features previously demonstrated as characteristic of human sweat glands subjected to prolonged stimulation.¹

We have performed biopsies of samples from the inguinal regions of a control patient and an HH patient. There was no significant morphological difference between either the eccrine glands or their ducts from the examined patients. The control patient exhibited slight distention of the gland with hyalin material inside, whereas the HH patient exhibited a larger volume of the same material, which corresponds to the secretion of these glands (Fig 2). Neither apocrine nor apoeccrine glands were observed in the patients studied. Glandular hyperfunctional alterations are not shown by optical microscopy. To analyze these alterations, ultramicroscopy and/or functional studies are required.

Aggravating and Attenuating Factors

HH is similar to other focal forms, such as axilla and palm-sole hyperhidrosis,¹³⁻¹⁵ in its aggravating factors: heat, stress, and physical exercise. Our initial group of HH patients have cited other aggravating factors, such as sexual activity, excessive intake of liquids, weight increase, premenstrual tension, prolonged sitting, and wearing clothing made of synthetic materials. The intensity of the disorder varies from patient to patient, depending on the combination and association of these factors.

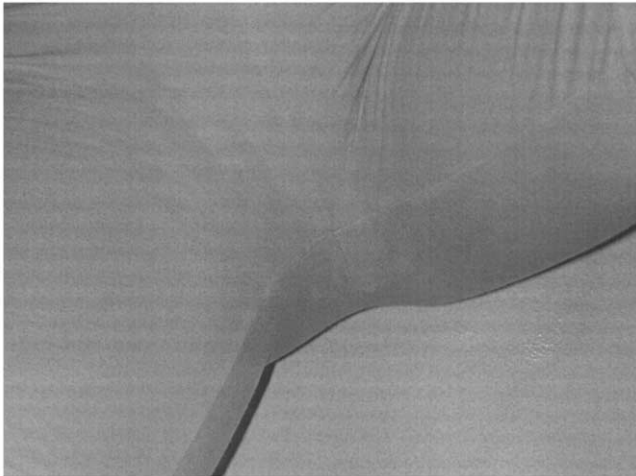


Figure 3. HH patient showing wet clotting even at cold temperatures.

Cold acts as an attenuating factor. Patient stress and activity levels, however, are both important aggravating factors. If these are intense, even cold temperatures may not reduce the problem. The absence of stress is also referred to by some patients as an attenuating factor.

Psychological and Social Aspects

Constant, excessive perspiration in the inguinal region is an embarrassing and unpleasant condition that makes daily activities difficult and interferes with the professional, leisure, and social activities of affected individuals. In severe cases, it can also limit certain occupations or tasks.²

Excess perspiration can produce large wet stains on clothes, leaving the fabric wet (Fig 3). This occurs in other forms of hyperhidrosis, and in other regions there is only one logical explanation for the presence of wet stains, ie, sweating. In the case of HH, however, the presence of such stains may be interpreted as indicating urinary incontinence or poor personal hygiene. This can cause a great deal of distress to the patient and can lead to embarrassment and social withdrawal. The resulting embarrassment is referred to by patients as being much worse than that produced by axillary hyperhidrosis.

Therefore, HH significantly affects the psychological and social behavior of these individuals. Patients frequently isolate themselves socially and adopt behaviors to conceal the problem. This includes avoidance of wearing light-colored clothing; a preference for dark clothing, clothing made of natural fibers, absorbent underwear; and also the frequent use of sanitary towels. Frequent bathing and changes of clothing are other measures adopted by HH sufferers to minimize the discomfort arising from the problem.

Associated Conditions

HH can be a trigger and a sustaining factor of other diseases common in the inguinal region. The most frequent are bacterial infections, such as folliculitis, erythrasma, and dermatitis. These can be facilitated by contact with clothing or products used in the area to decrease perspiration¹⁶ or by the increase in local moisture, with consequent skin maceration and proliferation of microorganisms. Bromhidrosis in the inguinal region is frequently mentioned by HH patients. Chromhidrosis and skin color changes in the inguinal region are also mentioned by these patients.

Diagnosis

Some patients with focal hyperhidrosis are distressed by apparently normal volumes of physiologic sweat.⁴ This also occurs with some HH sufferers. At least one of the two following criteria is needed for the diagnosis of HH:

1. Presence of intense sweating in the inguinal region, which causes evident humidity of the clothing and social embarrassment.
2. Measurement of the quantity of sweat by gravimetry >10 mg/min on each side, at $20\text{--}25^{\circ}\text{C}$ ($68\text{--}77^{\circ}\text{F}$), under one or more aggravating factors.

Treatment

Topical Treatments

Topical treatments are considered classic for focal hyperhidrosis. They are scarce and offer poor results of use in the inguinal region. Antiperspirants are considered medicines by the FDA (Food and Drug Administration), and they act to reduce the volume of secretion excreted by the eccrine glands and their ducts on the skin surface.^{17,18} Antiperspirant creams or lotions often contain glutaraldehyde, aluminum chlorohydroxide, formol, and its derivatives, and they also contain anticholinergic agents.^{14,17–20} These products should be applied to dry skin, after a cold bath, immediately before going to bed. They may cause contact dermatitis⁴ or leave a yellowish color on the skin.¹⁶

Medical Treatment

Medical treatment with antidepressant, anxiolytic, and anticholinergic drugs is not highly recommended.¹⁹ These drugs provide only partial relief of the perspiration and cause significant and undesired side effects, such as visual alterations, dry mouth, decreased libido, urinary problems, sedation, and postural hypotension. Some anticholinergic substances such as propantheline bromide, glycopyrrolate, and oxyphencyclimine have a transient effect²¹ and can cause urinary retention.^{16,21}

Other Treatments

Iontophoresis involves a complex process of ion transport through the skin by using a galvanic current.²² This process decreases the perspiration production in the treated areas.^{19,21} This therapy could be effective, with partial improvement.¹ Repeated treatments are required.⁴ Although there are devices with special configurations to treat the axilla, palm, and sole regions, there is no special configuration for the inguinal region.

Surgical treatments for focal hyperhidrosis include excision of sweating areas,⁴ curettage, and liposuction, as well as skin ablation.¹ These treatments are not considered suitable for the treatment of inguinal hyperhidrosis because of the particular histology and anatomy of the skin in the inguinal region. These procedures can result in unacceptable scars.

Endoscopic video-assisted thoracic sympathectomy, a surgical technique widely used to treat axillary and palm-sole hyperhidrosis,²³ can be used for the treatment of HH. The ganglia that are sectioned in the treatment of palm-sole hyperhidrosis are the same as those that pass through the inguinal region, and the level at which sectioning would be performed would not increase the degree of surgical risk involved. Nevertheless, thoracic sympathectomy has been shown to be of little effect in the treatment of sole hyperhidrosis, and it can be supposed that this would also be the case in the treatment of HH. Lumbar sympathectomy could also be performed to treat plantar or HH; however, in male patients, this treatment at the lumbar level can cause impotence. We have no knowledge of the use of endoscopic sympathectomy in the treatment of HH.

The intradermic application of type A botulinum toxin (BTX-A), although it provides only temporary reduction, is the best therapeutic option to consider because it is a safe and simple procedure that provides satisfactory results that improve the quality of life of treated HH patients.^{24,25}

BTX-A Treatment

BTX-A is an irreversible inhibitor of acetylcholine release from the presynaptic membranes of neuromuscular junctions, thus preventing cholinergic transmission to postganglionic neuroreceptors.⁴ Because apocrine, eccrine, and apoecrine glands respond to cholinergic stimuli, subcutaneous injections of BTX-A into the axilla result in complete cessation of sweating from all gland types.⁴ The effect can last >3 months but needs frequent application to maintain the results.^{4,24,26,27}

Technique

The procedure is not very painful, and anesthetic creams can be used before application to increase patient comfort. Depending on the density of hair in the



Figure 4. HH patient treated with Botox[®] reconstituted in 2 mL saline, 2 U of each 2 cm² (50 U per side; total dose of 100 U).

area to be treated, trichotomy of the region may be necessary. The iodine-starch test is performed in the area to be treated, and then the region that tested positive is marked with a surgical pen.

Application of 2 or 3 U of BTX-A (Botox[®]) per square centimeter is efficacious and long-lasting for hyperhidrosis treatment in varied locations. Therefore, the dose to be used in the inguinal region will depend on the size of the affected area²⁸ and on the intensity of the problem. Bearing in mind that the sweat glands are located about 2.5 mm below the skin,²⁹ the application should be intradermic, preferably using fine-gauge needles, such as 30-gauge. Application of BTX-A can also be performed by adapting the needle size of the BD Ultra Fine II syringe by using the lid of the needle cut as a shield to avoid overly deep injections.²⁷ The iodine-starch test should be repeated about 1 month after the procedure to identify any residual perspiring areas.

Results of BTX-A Application in the Inguinal Region

As previously described, the effect observed after intradermic injections of BTX-A is hypohidrosis or anhidrosis. Temporary reduction of sweating is obtained, and the duration of the effect is dose-dependent; there are also individual variations.

When treating any focal hyperhidrosis with BTX-A, an anhydrotic effect for about 6-8 months is obtained. Schnider and colleagues³⁰ treated 61 patients with hyperhidrosis and demonstrated a duration of BTX-A action of 34 weeks in patients with axillary hyperhidrosis and of 25 weeks in patients with palmar hyperhidrosis.

No study to date has described the ideal doses of BTX for the treatment of HH. The threshold doses of BTX-A for the treatment of hyperhidrosis depend on




Figure 5. Same halos resulting from the injection of 3 U in different dilutions (1 and 2 mL).

the severity of the condition.³¹ Two or 3 units of BTX-A per square centimeter can be used to treat the hyperhidrotic area in the inguinal region (Fig 4). The same dose of BTX-A (Botox[®]) diluted in 1 or 2 mL of 0.9% saline solution produces the same diffusion anhydrotic halo (Fig 5). The total recommended dose for the treat-

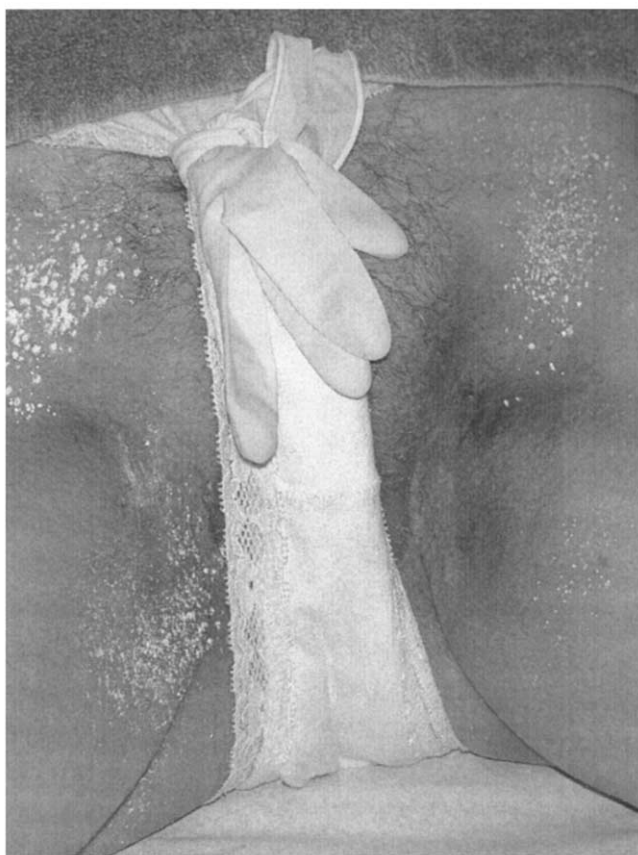


Figure 6. Residual sweating areas 1 month after Botox[®] treatment.



Figure 7. Edema immediately after injections of 3 U per site at the inguinal area.

ment of HH is 100 U. The effects usually last for 6 months or more. Lower doses, such as 60–80 U, can be used to treat less severe cases. Additional dose may be required in more severe cases. Minor's iodine-starch test can be done 30 days after treatment to evaluate the results and observe residual hyperhidrotic areas (Fig 6).

The only side effects observed are those related to the injections, such as small hematomas and temporary edema (Fig 7). In patients treated by us, no decrease in the muscle force of the inguinal region was observed after treatment.

Conclusions

Inguinal hyperhidrosis, or HH, is an uncommon condition and an infrequent complaint in medical offices. It causes significant social embarrassment, with consequent change in the psychological and social behavior of affected individuals. Until recently, there have been few satisfactory therapeutic alternatives available. Currently, treatment with BTX, though costly, can be considered a safe and very effective option to treat this form of focal hyperhidrosis.

References

1. Bovell DL, Clunes MT, Elder HY, et al. Ultrastructure of the hyperhidrotic eccrine gland. *Br J Dermatol* 2001;145:298–301.
2. Leung AK, Chan PYH, Choi MCK. Hyperhidrosis. *Int J Dermatol* 1999;38:561–7.
3. Hexsel D, Avé BR, Hexsel C, Dal Forno T. Inguinal Hyperhidrosis. In: Almeida AT, Hexsel D, eds. *Hyperhidrosis and Botulinum Toxin*. Author's Edition. São Paulo, 2003; 181:185.
4. Lonsdale-Eccles A, Leonard N, Lawrence C. Axillary hyperhidrosis: eccrine or apocrine? *Clin Exp Dermatol* 2003; 28:2–7.

5. Naumann M. Hypersecretory disorders. In: Moore P, Naumann M, editors. Handbook of botulinum toxin treatment, 2nd ed. Oxford: Blackwell-Science, 2003:343–59.
6. Quinton PM, Elder HY, Jenkinson DME, et al. Structure and function of human sweat glands. In: Laden K, editor. Antiperspirants and deodorants. New York: Marcel Dekker, 1999:17–57.
7. Murphy G. Histology of the skin. In: Elder D, Elenitsas R, Jaworsky C, et al, editors. Lever's histopathology of the skin, 8th ed. Philadelphia: Lippincott-Raven, 1997:27–8.
8. Champion RH. Disorders of sweat glands. In: Champion RH, Burton JL, Burns DA, Breathnach SM, eds. Rook/Wilkinson/Ebling, Textbook of Dermatology, 6th ed. Oxford: Blackwell Science, 1998:1985–2002.
9. Sato K, Leidal R, Sato F. Morphology and development of an apoeccrine sweat gland in human axillae. *Am J Physiol* 1987;252:R166–87.
10. Guyton AC, Hall JE. The nervous system: c. motor and integrative neurophysiology. In: Guyton AC, Hall JE, editors. Textbook of medical physiology, 9th ed. Philadelphia: W.B. Saunders Co, 1996:774–5.
11. Wenzel FG, Horn TD. Nonneoplastic disorders of the eccrine glands. *J Am Acad Dermatol* 1998;38:1–17.
12. Guyton AC, Hall JE. Metabolism and temperature regulation. In: Guyton AC, Hall JE, editors. Textbook of medical physiology, 9th ed. Philadelphia: W.B. Saunders Co, 1996:914–5.
13. Lauchli S, Burg G. Treatment of hyperhidrosis with botulinum toxin A. *Skin Therapy Lett* 2003;8(7):1–4.
14. Altman RS, Schwartz RA. Emotionally induced hyperhidrosis. *Cutis* 2002;69:336–8.
15. Ruchinskas RA, Narayan RK, Meagher RJ, et al. The relationship of psychopathology and hyperhidrosis. *Br J Dermatol* 2002;147:733–5.
16. Sampaio SAP, Rivitti EA. Hidroses. In: Sampaio SAP, Rivitti EA, eds. *Dermatologia*. São Paulo: Artes Médicas, 1998:308.
17. Draelos ZD. Antiperspirants and the hyperhidrosis patient. *Dermatol Ther* 2001;14:220–4.
18. Draelos ZD. Produtos de cuidados pessoais. In: Draelos ZD, editor. *Cosméticos em dermatologia*, 2nd ed. Revinter: Rio de Janeiro, 1999:227–35.
19. Tögel B, Greve B, Raulin C. Current therapeutic strategies for hyperhidrosis: a review. *Eur J Dermatol* 2002;12:219–23.
20. Edwards CJC, Mills AK. A guide to understanding antiperspirant formulation. In: Laden K, editor. *Antiperspirants and deodorants*, 2nd ed. New York: Marcel Dekker, 1999:233–58.
21. Seukeran DC, Highet AS. The use of topical glycopyrrolate in the treatment of hyperhidrosis. *Clin Exp Dermatol* 1998;23:204–5.
22. Karakoç Y, Aydemir EH, Kalkan MT, et al. Safe control of palmoplantar hyperhidrosis with direct electrical current. *Int J Dermatol* 2002;41:602–5.
23. Alric P, Branchereau P, Berthet JP, et al. Video-assisted thoracoscopic sympathectomy for palmar hyperhidrosis: results in 102 cases. *Ann Vasc Surg*. 2002;16:708–13.
24. Swartling C, Naver H, Lindberg M. Botulinum A toxin improves life quality in severe primary focal hyperhidrosis. *Eur J Neurol* 2001;8:247–52.
25. Tan SR, Solish N. Long-term efficacy and quality of life in the treatment of focal hyperhidrosis with botulinum toxin A. *Dermatol Surg* 2002;28:495–9.
26. Wollina U, Karamfilov T, Konrad H. High dose botulinum toxin type A therapy for axillary hyperhidrosis markedly prolongs the relapse-free interval. *J Am Acad Dermatol* 2002;46:536–40.
27. Almeida AT, Cernea SS. Tratamento da hiperidrose. In: Hexsel D, Almeida AT, editors. *Uso cosmético da toxina botulínica*. Porto Alegre: AGE, 2002:226–7.
28. Braune C, Ergbuth F, Birklein F. Dose thresholds and duration of the local anhidrotic effect of botulinum toxin injections: measured by sudorometry. *Br J Dermatol* 2001;144:111–17.
29. Naumann M, Hojman U, Bergmann I, et al. Focal hyperhidrosis: effective treatment with intracutaneous botulinum toxin. *Arch Dermatol* 1998;134:301–4.
30. Schnider P, Moraru E, Kittler H, et al. Treatment of focal hyperhidrosis with botulinum toxin type A: long-term follow-up in 61 patients. *Br J Dermatol* 2001;145:289–93.
31. Moraru E, Voller B, Auff E, et al. Dose thresholds and local anhidrotic effect of botulinum A toxin injections [Letter]. *Br J Dermatol* 2001;145:368.