

# Botulinum Toxin for Hyperhidrosis

## A Review

Alexander Grunfeld,<sup>1</sup> Christian A. Murray<sup>2</sup> and Nowell Solish<sup>2</sup>

1 Faculty of Medicine, University of Toronto, Women's College Hospital, Toronto, Ontario, Canada

2 Division of Dermatology, University of Toronto, Women's College Hospital, Toronto, Ontario, Canada

## Contents

Abstract	87
1. Definition and Etiology of Hyperhidrosis (HH)	88
2. Epidemiology	88
3. Burden of Disease	89
4. Pathophysiology	89
5. Diagnostic Approach	89
6. Management of Primary Focal HH	90
6.1 Botulinum Toxin	92
6.1.1 Axillary HH	93
6.1.2 Palmar HH	95
6.1.3 Plantar HH	95
6.1.4 Craniofacial HH	96
6.1.5 Other Types of Focal HH	96
6.1.6 General Considerations	96
7. Botulinum Toxin Injection Tips	96
7.1 Minor's Iodine-Starch Test	96
7.2 Anesthesia	97
7.2.1 Alternatives and Adjuncts	97
7.3 Dilution and Injection	97
7.3.1 General Instructions	97
7.3.2 Axillary HH	98
7.3.3 Palmar and Plantar HH	98
7.3.4 Craniofacial HH	98
8. Conclusion	98

## Abstract

Primary focal hyperhidrosis is a disorder of idiopathic excessive sweating that typically affects the axillae, palms, soles, and face. The disorder, which affects up to 2.8% of the US population, is associated with considerable physical, psychosocial, and occupational impairments. Current therapeutic strategies include topical aluminum salts, tap-water iontophoresis, oral anticholinergic agents, local surgical approaches, and sympathectomies. These treatments, however, have been limited by a relatively high incidence of adverse effects and complications. Non-surgical treatment complications are typically transient, whereas those of surgical therapies may be permanent and significant. Recently, considerable evidence suggests that botulinum toxin type A (BTX-A) injections into hyperhidrotic areas can considerably reduce focal sweating in multiple areas without major adverse effects. BTX-A has therefore shown promise as a potential replacement for more invasive treatments after topical aluminum salts have failed. This article reviews the

epidemiology, diagnosis, and management of primary focal hyperhidrosis, with an emphasis on recent research evidence supporting the use of BTX-A injections for this indication.

## 1. Definition and Etiology of Hyperhidrosis (HH)

Hyperhidrosis (HH) is a disorder of excessive sweating out of proportion with thermoregulatory requirements. Patients sweat excessively mostly in response to emotional and thermal stimuli, but also in response to other triggers (e.g. fine manual tasks, exercise) and occasionally even spontaneously.<sup>[1,2]</sup> Since no standardized definition of 'excessive' sweating exists, clinicians typically base their diagnosis in part on subjective measures that estimate how HH affects a patient's quality of life (QOL). In practice, sweating is excessive or abnormal if it significantly interferes with daily life.

HH can be classified as either focal or generalized (table I). Focal HH involves excessive sweating in a typically bilateral and symmetric distribution, although it may present unilaterally.<sup>[3,4]</sup> The axillae, palms, soles, and face are most commonly affected.<sup>[5,6]</sup> Generalized HH, in contrast, affects the entire body. A further distinction can be made between primary and secondary HH. Primary or idiopathic HH is of unknown etiology and almost invariably presents as focal HH. Secondary HH, a detailed discussion of which is beyond the scope of this article, may be due to a wide variety of disorders, including endocrine, metabolic, neurologic, toxic, neoplastic, infectious, or cardiorespiratory conditions.<sup>[7-10]</sup> Secondary HH most often manifests as generalized HH, but can also present in a localized, focal pattern. In the context of this article, the term focal HH will nevertheless be used to imply primary focal HH.

## 2. Epidemiology

Primary focal HH is not a rare condition, as it affects up to 2.8% of the US population, a prevalence comparable to that of psoriasis.<sup>[6,12]</sup> Although the condition affects men and women equally, women are more likely to seek medical attention for their symptoms.<sup>[5,6]</sup> Even so, nearly two-thirds of individuals with focal HH do not consult their physician about their condition,<sup>[6]</sup> presumably because of either social embarrassment or a lack of awareness that they have a treatable medical condition. As a result, the majority of individuals with focal HH are undiagnosed and untreated.

Primary focal HH most commonly affects individuals aged 25–64 years.<sup>[6]</sup> The average age of onset is 25 years, but this varies depending on the body area affected.<sup>[4-6]</sup> Palmar HH tends to begin in childhood and early adolescence,<sup>[5,13]</sup> whereas axillary HH tends to have a post-pubertal onset.<sup>[4-6,13]</sup> The natural history

**Table 1.** Examples of causes of generalized and focal hyperhidrosis<sup>[7,9-11]</sup>

<b>Generalized hyperhidrosis</b>	
Endocrine and metabolic	Hyperthyroidism Hyperpituitarism Diabetes mellitus Hypoglycemia Gigantism and acromegaly Menopause Pregnancy
Neurologic	Parkinson disease Spinal cord injury Cerebrovascular accident
Drugs	Antidepressants Antiemetics (many more examples exist)
Toxic	Alcohol abuse Substance abuse or withdrawal
Neoplastic	Myeloproliferative disorders Hodgkin lymphoma Carcinoid tumors Pheochromocytoma
Infectious	Febrile illness Chronic infections
Cardiovascular	Shock Heart failure
Respiratory failure	
<b>Focal hyperhidrosis</b>	
Primary idiopathic	Axillary Palmar Plantar Craniofacial
Gustatory sweating	Frey syndrome Citric acid Coffee Chocolate Peanut butter Spicy food
Associated with neuropathies	
Secondary to spinal disease/injury	

of focal HH is uncertain, but some evidence suggests spontaneous regression over time, given the low prevalence of the disorder among the elderly.<sup>[5,6]</sup>

The axillae (51%), soles (30%), palms (24%), and face (10%) are most commonly affected in focal HH.<sup>[5,6]</sup> Additional areas

such as the back, chest, abdomen, forearm, genitals, and lower extremities can also be involved.<sup>[5]</sup> Patients often note more than one area of excessive sweating; 81.4% of patients with axillary HH, for instance, experience excessive sweating in other areas.<sup>[6]</sup> Focal HH is generally described as a symmetric phenomenon, but it may be unilateral in 21% and 6% of cases of axillary and palmar HH, respectively.<sup>[4]</sup> A unilateral presentation, although less common, should therefore not be taken as strong evidence against a diagnosis of primary focal HH.

Studies have repeatedly discovered a strong family history of focal HH among individuals with this condition, with most estimates of affected family members ranging from 30% to 50%.<sup>[14]</sup> Both early onset<sup>[5,13]</sup> and axillary involvement<sup>[4,15]</sup> are associated with a stronger family history. The inheritance of focal HH is likely autosomal dominant with variable penetrance and expressivity.<sup>[16]</sup> Based on calculations of allelic probability, a child born to a parent with palmar HH has a 25% chance of also developing the disorder.<sup>[16]</sup>

### 3. Burden of Disease

Focal HH may lead to a wide range of secondary medical conditions, such as bacterial or fungal overgrowth,<sup>[7,17,18]</sup> muscle cramps,<sup>[19]</sup> eczematous dermatitis,<sup>[17,20-23]</sup> and additional dermatologic conditions,<sup>[24]</sup> as well as anxiety and other psychological disturbances.<sup>[2,4,6,7,18,25-27]</sup> Most important to patients, however, is the effect that HH has on their QOL and psychosocial well-being. Several studies using validated QOL measures suggest that HH is associated with impairments in QOL comparable to those associated with severe psoriasis or dermatitis/eczema as well as severe chronic disease states such as end-stage renal disease, rheumatoid arthritis, and multiple sclerosis.<sup>[4,28-30]</sup>

All patients with HH experience some degree of physical discomfort, psychosocial impairment, and functional disruption as a consequence of their sweating.<sup>[2,4,6,7,25-28,30-34]</sup> Despite these negative consequences, up to 62% of patients do not even realize that they have a medical condition and may consequently blame themselves.<sup>[6]</sup>

### 4. Pathophysiology

Human skin has approximately 2–4 million sweat glands, of which there are two functionally distinct types: eccrine and apocrine.<sup>[35,36]</sup> Apocrine glands, found predominantly in the groin and axillae, are not thought to play a significant role in HH. Eccrine glands, which are the most numerous, are distributed in the deep dermis over almost the entire body. They are especially concentrated on the soles, forehead, axillae, palms, and cheeks.<sup>[37]</sup> On the palms, they are the only sweat gland present. Eccrine glands

produce a thin, odorless solution hypotonic to plasma that gives rise to HH if secreted in excess. Eccrine glands are important in thermoregulation, yet they also respond to gustatory and emotional stimuli, such as stress, anxiety, fear, and pain.<sup>[35,36]</sup> They are innervated by postganglionic sympathetic cholinergic fibers, but also respond to adrenergic stimuli, albeit to a lesser extent.<sup>[35]</sup>

According to histologic studies, neither the number, density, nor size of eccrine glands is increased among individuals with HH.<sup>[38]</sup> Recent data on the ultrastructure of hyperhidrotic eccrine glands suggest that these glands are not morphologically abnormal, but purely hyperactive.<sup>[39]</sup> HH therefore is likely due to neurogenic overactivity of otherwise normal eccrine glands in the affected area.<sup>[40,41]</sup> Some evidence suggests that this increased sympathetic activity may occur at the upper dorsal sympathetic ganglia T2 and T3.<sup>[42,43]</sup> The pathophysiology of focal HH is poorly understood, but likely involves a complex autonomic and regulatory dysfunction in both the sympathetic<sup>[43,44]</sup> and parasympathetic<sup>[45]</sup> pathways. Evidence suggests that hyperexcitability of the somato-sympathetic reflex circuits involved in eccrine secretion may account for the apparent neurogenic overactivity.<sup>[40]</sup>

### 5. Diagnostic Approach

The Multi-Specialty Working Group on the Recognition, Diagnosis, and Treatment of Primary HH recommends that primary focal HH should be diagnosed when “focal, visible, excessive sweating of at least 6 months duration” is present without apparent cause in conjunction with at least two of the following six criteria:<sup>[46]</sup>

- bilateral and relatively symmetric distribution;
- impairment of daily activities;
- frequency of at least one episode per week;
- age of onset <25 years;
- positive family history;
- cessation of focal sweating during sleep.

The patient history and examination should focus on the pattern of sweating (location, duration, frequency, volume, symmetry, specific triggers, and nocturnal sweating), age of onset, impact on QOL, family history, and any suggestion of a secondary etiology.<sup>[11,46,47]</sup> The review of systems will assist in ruling out potential secondary causes of HH and in documenting any contraindications to therapy.<sup>[41,46]</sup> In the absence of a secondary etiology, laboratory tests generally are not needed. Further components of the work-up of a hyperhidrotic patient should include evaluation of the severity of sweating, the impairment of daily activities, and the distribution of HH.

Both quantitative and subjective means of assessing the severity of sweating among hyperhidrotic patients exist. Although no standardized definition of focal HH exists, normal sweating

may be defined quantitatively as  $<1 \text{ mL/m}^2/\text{min}$  of eccrine sweat production at rest and at room temperature.<sup>[35]</sup> Although quantitative measures such as gravimetry are often used in research settings, their use is not practical in clinical settings. Compared with quantitative measures, subjective ratings such as visual analog scales actually have a relatively high level of diagnostic sensitivity and specificity.<sup>[48,49]</sup>

Since the diagnosis of focal HH requires impairment of daily activities,<sup>[46]</sup> clinicians should attempt to assess QOL in patients with excessive sweating. Although formalized assessment tests are not required in routine clinical practice, the four-item Hyperhidrosis Disease Severity Scale (HDSS)<sup>[5,6,32,50,51]</sup> [see table II] may help clinicians quickly determine the level of interference with daily activities caused by HH.<sup>[47]</sup> Treatment guidelines have also used HDSS scores to stratify the management of patients with focal HH according to disease severity.<sup>[6,46]</sup>


Once the diagnosis of primary focal HH has been made, semi-quantitative techniques may prove useful in determining the precise pattern of sweating and in monitoring the effectiveness of treatment over time.<sup>[52,53]</sup> A Minor's iodine-starch test is most commonly used for this purpose (figure 1). This test can be used to map the area of excess sweating prior to initiating local treatments with botulinum toxin or surgery, but does not provide accurate information on the quantity of sweat produced.<sup>[26,41,54-56]</sup>

## 6. Management of Primary Focal HH

Treatment for primary focal HH aims to reduce the level of sweat secreted to a level that is acceptable to the patient. Rather than striving to decrease sweat production by a predetermined percentage, the ultimate goal of treatment is to improve the patient's QOL, which can be readily assessed in clinical settings using the HDSS. For individuals with severe HH (HDSS 3–4), treatment success is defined as a 1- to 2-point reduction in an HDSS score to 2 or less. Treatment success in patients with mild or moderate HH (HDSS 1–2) involves a reduction of at least 1 point on the HDSS. Treatment failure entails either no change in HDSS scores after 1 month of therapy or an intolerability of the treatment or its adverse effects. In the absence of intolerability,

**Table II.** Hyperhidrosis Disease Severity Scale (HDSS)<sup>[51]</sup>

My sweating is never noticeable and never interferes with my daily activities	Score 1
My sweating is tolerable but sometimes interferes with my daily activities	Score 2
My sweating is barely tolerable and frequently interferes with my daily activities	Score 3
My sweating is intolerable and always interferes with my daily activities	Score 4



**Fig. 1.** A Minor's iodine-starch test results in purple-to-black discoloration that delineates the area affected by excessive sweating. Panel (a) shows the colorimetric reaction that occurs in a patient with axillary hyperhidrosis. Panel (b) shows the results of a Minor's test in the same patient following botulinum toxin type A treatment of his axilla.

options for treatment failure include repeating the treatment once (e.g. botulinum toxin type A [BTX-A] injections), or switching or combining therapies.

The many available treatment modalities can be categorized as either conservative (table III) or surgical (table IV). These options vary in their efficacy, adverse effects, cost, and duration of effect.<sup>[57]</sup> Four treatment guidelines for focal HH<sup>[46,47,58,59]</sup> and one algorithm for palmoplantar HH specifically<sup>[60]</sup> have been proposed (see table V). These guidelines generally agree that the severity of HH, as assessed using the HDSS, should be used in conjunction with the patient's own wishes and medical characteristics (e.g. co-morbidities) to guide the choice of treatment.<sup>[46,47]</sup> In general,

**Table III.** Conservative treatment options for primary focal hyperhidrosis (HH)

Type of therapy	Mechanism of action	Type(s) of HH	Advantages and disadvantages	Usage recommendations
Topical aluminum chloride hexahydrate	Causes physical obstruction of eccrine ducts by combining with intraductal keratin fibrils to form a plug	Axillary, palmar, plantar	Usually requires 10–50% aluminum chloride hexahydrate to effectively treat HH <sup>(61)</sup> Skin irritation common at high doses	Initial concentration (in absolute ethanol or salicylic acid gel): axilla: 10–12% (up to 35%); palmar/plantar: 20% (up to 50%); craniofacial: 10% (up to 20%) Technique: apply to dry area at bedtime, wash off after 6–8 h Frequency: three to seven times per wk until euhydrotic Maintenance: every 1–3 wk
astringent agents (e.g. formaldehyde)	Transiently block eccrine pores	Axillary, palmar, plantar	High rates of skin irritation, discoloration, and allergic sensitization leading to contact dermatitis <sup>(18,62,63)</sup>	Although some authors have recommended 10% glutaraldehyde solution in water with 1.65% bicarbonate applied twice per wk, <sup>(64,65)</sup> we do not recommend these agents as a first-line treatment
anticholinergics (e.g. glycopyrrrolate)	Competitively inhibit acetylcholine at the neuroglandular synapses of eccrine glands, thereby interfering with neuroglandular signaling	Craniofacial, axillary, palmar, plantar	Relatively low efficacy, poor absorption, and cutaneous and systemic adverse effects <sup>(18,66–69)</sup>	Topical glycopyrrrolate (0.5–4% cream, aqueous solution or pads) is primarily indicated for craniofacial HH <sup>(70,71)</sup> and various types of gustatory sweating (Frey syndrome, <sup>(72)</sup> diabetic, <sup>(73,74)</sup> and compensatory <sup>(75)</sup> )
anesthetics (e.g. lidocaine [lignocaine], prilocaine)	Presumably block sympathetic nerve fibers that supply eccrine glands	Axillary, palmar, plantar	Impractical due to low efficacy and short duration of effect <sup>(18,76)</sup>	Not recommended
iontophoresis	Uses electrical current to enhance percutaneous absorption of ions, leading to either obstruction of distal eccrine ducts or functional disruption of eccrine gland secretion	Axillary, palmar, plantar	Most commonly uses tap water, but anticholinergics may also be added (increased efficacy but more frequent systemic adverse effects, e.g. dry or sore mouth and throat) <sup>(77,78)</sup> Skin irritation, dryness, and peeling at treatment site (especially axillae) <sup>(79,80)</sup> Very time consuming <sup>(81)</sup>	Technique: direct current 10–20 mA for 20–30 min per session (switch current direction midway during each session) Frequency: every other day until euhydrotic (usually six to ten sessions) Maintenance: every 1–4 wk

Continued next page

Type of therapy	Mechanism of action	Type(s) of HH	Advantages and disadvantages	Usage recommendations
Oral (systemic) agents				
anticholinergics (e.g. glycopyrrolate)	Competitively inhibit acetylcholine at the neuroglandular synapses of eccrine glands, thereby interfering with neuroglandular signaling	Axillary, palmar, plantar	High doses usually required to inhibit sweating, leading to unpleasant and often intolerable adverse effects (e.g. dry mouth, blurred vision, urinary retention, constipation, tachycardia) <sup>(82,83)</sup>	Oral glycopyrrolate 1–2 mg one to three times daily
Botulinum toxin type A injections	Inhibit presynaptic release of acetylcholine and bind to acetylcholine receptors at the postsynaptic membrane, thereby disrupting the sympathetic input to eccrine glands	Axillary, palmar, plantar, craniofacial	Considerably reduce axillary, <sup>(25,84-86)</sup> palmo/plantar, <sup>(86-88)</sup> and craniofacial sweating <sup>(86,87)</sup> for 4–12 mo Minor adverse effects: injection-related pain; mild numbness, paresthesiae, and small hematomas at the injection site; transient weakness of intrinsic muscles of the hand <sup>(94,95,98)</sup>	Dose: axilla: 1 U/cm <sup>2</sup> (50–100 U/axilla); palm: 1.5–2 U/cm <sup>2</sup> (100–150 U/palm); sole: 1.5–2 U/cm <sup>2</sup> (150–200 U/sole); craniofacial: variable Frequency: once; repeat once more if treatment fails Maintenance: every 4–6 mo (on average) See Botulinum Toxin Injection Tips (section 7)

conservative approaches such as topical therapies should be attempted before surgical options, even in cases of severe HH.<sup>[46]</sup> If monotherapy is insufficient, the combination of topical with other conservative therapies is encouraged prior to considering surgical interventions.<sup>[47,59]</sup> Recommendations for combining treatment modalities are currently based solely on expert consensus,<sup>[47,59]</sup> as no research to date has examined the efficacy of combination therapy versus monotherapy. Surgical treatments should be reserved for those individuals with HDSS scores of 3 or 4 who do not respond to repeated trials of conservative mono- or combination therapy and whose type of focal HH is amenable to surgical intervention.<sup>[47]</sup>

### 6.1 Botulinum Toxin

BTX, which is produced by the anaerobic bacillus *Clostridium botulinum*, is a potent neurotoxin that inhibits the presynaptic release of acetylcholine and binds to acetylcholine receptors at the postsynaptic membrane.<sup>[122]</sup> When the toxin is applied using multiple injections to the affected hyperhidrotic area, it causes a localized, long-lasting yet reversible reduction in cholinergic transmission. Because eccrine glands are innervated by postganglionic sympathetic cholinergic fibers, they are effective targets for BTX. Given that the pathophysiology of focal HH likely involves neurogenic hyperactivity rather than structural abnormalities in eccrine glands,<sup>[39]</sup> a localized neuroglandular intervention seems ideal for the treatment of focal HH.

Of the seven different BTX serotypes that have been identified, BTX-A appears to be the most potent. BTX-A is available in the US as Botox<sup>®</sup> (Allergan Inc., Irvine, CA, USA) and in Europe as both Botox<sup>®</sup> and Dysport<sup>®</sup> (Speywood Pharmaceuticals Inc., Maidenhead, UK). The two formulations do not differ significantly in their efficacy or duration of effect, but Dysport<sup>®</sup> may be associated with more adverse effects when used for palmar HH.<sup>[123]</sup> One unit of Botox<sup>®</sup> is approximately equal to 3–4 units of Dysport<sup>®</sup>.<sup>[123-125]</sup> Botox<sup>®</sup> has been approved by the US FDA and Canada's Health Protection Branch for the treatment of axillary HH, glabellar lines (cosmetic), and several conditions of spasticity or spasm, such as blepharospasm, strabismus, and cervical dystonia. It has also been used off-label to successfully treat other facial wrinkles, migraine headaches, and other spasticity and tremor disorders.<sup>[126]</sup>

Since intradermal injections of BTX-A were first shown to be efficacious for the management of axillary HH in 1996,<sup>[84]</sup> numerous studies have supported the safety and efficacy of this treatment for axillary, palmar, plantar, and craniofacial HH. Most importantly, BTX can considerably improve QOL in severely affected patients.<sup>[27,32,33,50,127]</sup> Currently, Botox<sup>®</sup> is the only BTX-A formulation approved in Canada and the US for the

**Table IV.** Surgical treatment options for primary focal hyperhidrosis (HH)

Type of therapy	Mechanism of action	Type(s) of HH	Comments
Tissue excision	Excision of subcutaneous axillary sweat glands with or without overlying skin	Axillary	Usually permanent and relatively effective (50–90%) <sup>[99]</sup> High rates of complications (e.g. infection, bleeding, delayed healing, flap necrosis, hypertrophic and constrictive scarring) <sup>[99–101]</sup>
Minimally invasive surgery (curettage, liposuction, or combined suction-curettage)	Successful due to either removal or destruction of sweat glands or disruption of the neurovascular supply to these glands	Axillary	Higher efficacy (usually >90%) and fewer complications than excision <sup>[102–108]</sup> Minor complications (e.g. infection, superficial skin erosions, paresthesiae, ecchymoses, hematomas, seromas, fibrotic bands, skin retractions) <sup>[107,108]</sup> High recurrence rate (up to 23.8% by 6 mo) <sup>[107,109–111]</sup>
Endoscopic thoracic sympathectomy	Destroys T2 and/or T3 sympathetic ganglia via excision, radiofrequency, or electrocautery ablation, <sup>[112,113]</sup> or ganglion clamping <sup>[112,114]</sup>	Palmar, facial, axillary	Satisfactory control of sweating in up to 98%, <sup>[115]</sup> 83%, <sup>[116]</sup> and 63% <sup>[115]</sup> of patients with palmar, facial, and isolated axillary HH, respectively Moderate risk of recurrence (up to 8.8%) <sup>[117]</sup> Compensatory HH in 52.3%: subjective and objectively measurable increases in sweating in areas other than those made dry by sympathectomy <sup>[118]</sup> Compensatory HH begins 2–8 wk following endoscopic thoracic sympathectomy, may progress, and does not improve over time; it most commonly affects the back, chest, abdomen, and lower limbs High rate of patient dissatisfaction (up to 11.5%), <sup>[117]</sup> most commonly due to compensatory HH <sup>[119–121]</sup> Other complications include excessively dry hands, gustatory sweating, phantom sweating, Horner syndrome, neuropathic complications, and perioperative complications (e.g. pneumothorax, cardiac arrest)

treatment of axillary HH.<sup>[128]</sup> However, data demonstrating the efficacy of both Dysport<sup>®</sup> <sup>[125,129]</sup> and BTX-B (Myobloc<sup>®</sup>, Elan Pharmaceuticals, South San Francisco, CA, USA)<sup>[130–134]</sup> suggest that these may also be effective agents for this disorder.

Currently, BTX-A is delivered exclusively via intradermal injections for the treatment of focal HH. Although not extensively studied, potential future delivery options for BTX-A include topical administration<sup>[135,136]</sup> and iontophoresis.<sup>[137]</sup>

### 6.1.1 Axillary HH

The efficacy of BTX for the treatment of axillary HH has been evaluated in more than 20 prospective, observational, or placebo-controlled studies,<sup>[25,27,31–33,50,56,84–88,127,138–147]</sup> three of which were large, double-blind, placebo-controlled trials.<sup>[32,56,85]</sup> Across these studies, the duration of anhidrosis in the axillae usually ranged from 4 to 10 months, with some studies showing that treatment remains effective for up to 14 months.<sup>[25,84–86]</sup> Repeated BTX-A injections yield a similar duration of symptom relief, suggesting that patients do not develop treatment resistance.<sup>[31,56]</sup> Anhidrosis usually begins within 7–10 days following BTX-A

injections. The reduction in sweating symptoms is accompanied by dramatic improvements in several QOL measures, including general QOL, emotional status, ability to participate in daily and social activities, occupational productivity, and time spent treating HH symptoms.<sup>[27,32,33,50,127]</sup> Patients are extremely satisfied with the results of BTX-A treatment, with up to 98% willing to recommend the therapy to other individuals with axillary HH.<sup>[85]</sup>

### Adverse Events

Adverse effects associated with BTX-A treatment for axillary HH are minor. In one study,<sup>[56]</sup> 5% of patients treated with BTX-A perceived compensatory increases in sweating in non-axillary regions, although this increase was not measured quantitatively, nor was it reported in other studies. Pain associated with intradermal injections of BTX is usually minimal in the axillae. Both skin and air cooling have nevertheless been effective in reducing injection-related pain when it does occur.<sup>[148]</sup> Subcutaneous injections may also be less painful than dermal injections while maintaining a similar level of efficacy.<sup>[149]</sup>

**Table V.** Treatment algorithm for primary focal hyperhidrosis (FH), as recommended by the Canadian Hyperhidrosis Advisory Committee<sup>47a,b</sup>

Location	Severity <sup>c</sup>	First line	Second line	Third line	Fourth line	Fifth line
Axillary	Mild	Topical ACH (10–35%)	BTX-A (50–100 U/axilla)	Local surgery	N/A	N/A
	Moderate/severe	Topical ACH (10–35%) or BTX-A (50–100 U/axilla)	Topical ACH and BTX-A	± Oral anticholinergic (adjunct or alternative)	Local surgery	ETS
Palmar	Mild	Topical ACH (10–50%)	Iontophoresis or BTX-A (100–150 U/palm)	Topical ACH and (iontophoresis or BTX-A)	N/A	N/A
	Moderate/severe	Topical ACH (10–50%) or iontophoresis or BTX-A (100–150 U/palm)	± Oral anticholinergic (adjunct or alternative)	ETS	N/A	N/A
Plantar	Mild	Topical ACH (20–50%)	BTX-A (150–200 U/sole) or iontophoresis	Topical ACH and (iontophoresis or BTX-A)	N/A	N/A
	Moderate/severe	Topical ACH (20–50%) or iontophoresis or BTX-A (150–200 U/sole)	± Oral anticholinergic (adjunct or alternative)	N/A	N/A	N/A
Craniofacial	Any severity	Topical ACH (10–20%) or BTX-A (up to 100 U) or oral anticholinergic	ETS (HDSS 3–4 only)	N/A	N/A	N/A

a See table III for usage recommendations for conservative therapies.

b If treatment failure occurs (i.e. no change in the HDSS score after 1 mo of therapy) in the absence of intolerance to the treatment, the therapy may be repeated once (in the case of BTX-A) or another therapy in a given column may be attempted before moving across columns.

c Severity is determined using HDSS scores: mild (HDSS 1–2) or moderate/severe (HDSS 3–4).

**ACH** = aluminum chloride hexahydrate; **BTX-A** = botulinum toxin type A injections; **ETS** = endoscopic thoracic sympathectomy; **HDSS** = Hyperhidrosis Disease Severity Scale; **N/A** = not applicable.



### 6.1.2 Palmar HH

The beneficial effect of BTX-A on palmar HH has been demonstrated in numerous open-label studies and case reports,<sup>[26,86-93,150-154]</sup> and in one small single-blind<sup>[94]</sup> and two small, double-blind, placebo-controlled trials.<sup>[95,98]</sup> Efficacy, measured both quantitatively and subjectively, was around 80–90% in most of these studies. The duration of anhidrosis is shorter than in axillary HH, lasting approximately 6 months, and ranging from 4 to 12 months.<sup>[86-95]</sup> Response rates also vary more than in the treatment of axillary HH.<sup>[155]</sup>

#### Adverse Events

Transient weakness of the intrinsic hand muscles is the most noteworthy adverse event when using BTX for palmar HH.<sup>[87-90,93-95,151,152,156]</sup> The weakness usually begins after 1–3 days and resolves within 10–14 days.<sup>[94]</sup> In one Botox<sup>®</sup> study, subjective hand weakness occurred in 45–77% of treated patients, with higher rates occurring when higher dosages were used.<sup>[94]</sup> Quantitatively measured handgrip strength is generally normal in most patients, yet finger pinch strength is often reduced. If injections are meticulously placed high into the dermis, deep penetration of BTX-A to a point where it affects intrinsic muscle function may be prevented.<sup>[98]</sup> Given the high incidence of transient weakness of the intrinsic hand muscles following BTX treatment, clinicians should counsel patients regarding the potential consequences and dangers of poor fine motor control.

Intense pain and soreness are also experienced during the procedure and for up to 1–2 days thereafter due to the multiple injections into the palm, making this treatment difficult to tolerate.<sup>[94,157]</sup> Proper anesthesia is thus crucial to ensure patient compliance. Attempts to reduce injection-related pain have included topical anesthetics (e.g. lidocaine [lignocaine]<sup>[155]</sup> or tetracaine<sup>[158]</sup>); cryoanalgesia with ice,<sup>[159]</sup> cold air,<sup>[148]</sup> or dichlorotetrafluoroethane;<sup>[160,161]</sup> regional nerve blocks;<sup>[162-165]</sup> intravenous regional anesthesia (IVRA; Bier's block);<sup>[166,167]</sup> needle-free injection (e.g. MED-JET<sup>®</sup>);<sup>[157,168]</sup> and vibration anesthesia.<sup>[41,159,169]</sup> Patients should be counseled on the potential adverse effects of anesthesia, such as vascular puncture, impaired hand dexterity, and neuropathies from repeated nerve injuries.<sup>[162,163]</sup> The present authors currently employ topical ice cubes (i.e. cryoanalgesia), as described by Smith et al.,<sup>[159]</sup> as first-line anesthesia, with vibration and regional (wrist block) anesthesia as second- and third-line options, respectively.

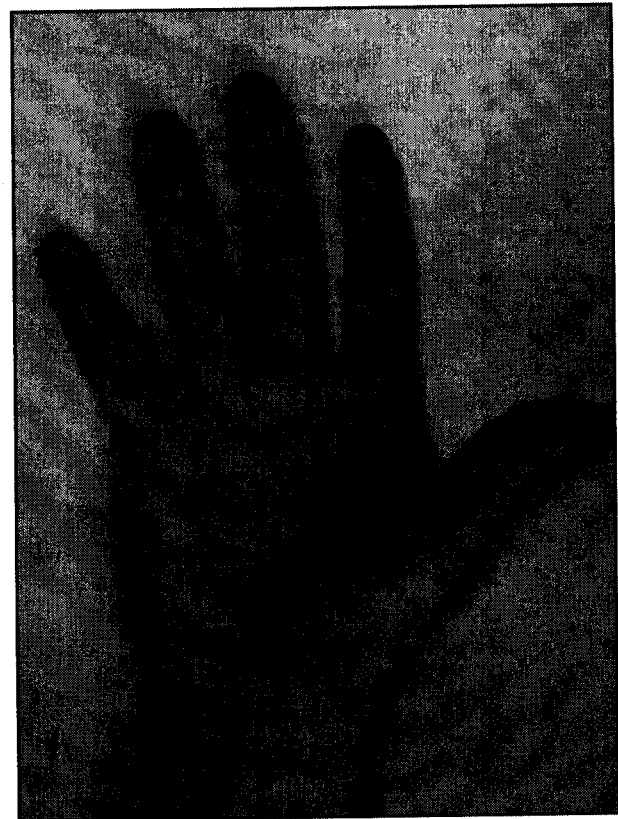
Additional adverse events during BTX-A treatment for palmar HH include mild numbness, paresthesias, and small hematomas at the injection site. These adverse events are mild, transient, and uncommon, occurring in less than 10% of treated patients.<sup>[95,98]</sup>

#### Dosing

The doses required to effectively treat palmar symptoms tend to be higher than for axillary HH, often ranging from 100 to 240 U of Botox<sup>®</sup>.<sup>[26,87,89,90,150,152,153,156]</sup> However, in one randomized, single-blind trial comparing 50 U with 100 U BTX-A per hand the investigators found similar efficacy for both dosages, with only a trend toward higher patient satisfaction in the 100-U dose group.<sup>[94]</sup> The higher dose of Botox<sup>®</sup> was nevertheless associated with an increased incidence of subjective hand weakness and reduced finger pinch strength compared with the lower dose. It may thus be prudent to initiate treatment with 50 U BTX-A per hand, even though recent treatment guidelines suggest using at least 100 U.<sup>[47]</sup> Doses should be tailored to the size of the palm, with injections of approximately 2–3 U of Botox<sup>®</sup> spaced every 1–2 cm (see figure 2).

### 6.1.3 Plantar HH

Few studies have examined BTX treatment for plantar HH, as the thickened stratum corneum on the soles of feet makes intradermal injections more challenging.<sup>[46]</sup> Injections are also quite painful because of the dense innervation of the area. Most



**Fig. 2.** Map for placing botulinum toxin type A injections into the palm for palmar hyperhidrosis. Injections should be placed every 1–2 cm.

patients therefore require an ankle block prior to receiving injections.<sup>[162]</sup> Use of the Dermojet<sup>®</sup> to inject the soles with BTX-A may also decrease injection-related pain but may be less effective than intradermal injections.<sup>[170,171]</sup>

Uncontrolled studies have found that BTX-A treatment of plantar HH may be as effective as for palmar HH, requiring similar dosages and yielding approximately 6 months of symptom relief and improved QOL.<sup>[86,170-173]</sup> Adverse effects include both pain and hematomas at injection sites.<sup>[86,170]</sup> In the authors' experience, treatment efficacy is much lower than for the palms or axillae, and up to 50% of patients are unsatisfied with treatment. In addition, higher doses of 200 U or more of BTX-A per sole may be needed. However, we have noted that up to 40% of patients who are treated with BTX-A for palmar HH alone have reported improvement in their plantar HH.

#### 6.1.4 Craniofacial HH

BTX-A has been successful in the treatment of frontal or forehead HH, effecting a reduction in sweating of approximately 75% that is maintained for at least 5 months.<sup>[88,96,174]</sup> Injections are usually made in a band near the hairline. Mild weakness of the frontalis muscle appears to be the only adverse effect, lasting 1–12 weeks and sometimes resulting in a mild brow ptosis.<sup>[96,97]</sup>

#### 6.1.5 Other Types of Focal HH

BTX-A has also been used in the treatment of several other focal HH conditions, including HH of the anal fold and inguinal region.<sup>[175,176]</sup> In addition, BTX-A may be effective in treating the focal HH associated with chronic anal fissures.<sup>[177]</sup>

#### 6.1.6 General Considerations

Although BTX-A treatment has been investigated for nearly all types of focal HH, it is currently only FDA approved for the treatment of axillary HH. Clinicians should keep in mind that treatment of palmoplantar and craniofacial HH using BTX-A is considered off-label. Clinicians should also be aware of the absolute and relative contraindications to BTX-A treatment (see table VI).<sup>[178]</sup> There is a risk that BTX-A could unmask or exacerbate neuromuscular disease (e.g. myasthenia gravis,<sup>[179,180]</sup> Lambert-Eaton syndrome<sup>[181]</sup>), but this risk remains low, and patients with neuromuscular disease have been treated safely with BTX-A (e.g. for cervical dystonia).<sup>[182,183]</sup> Although pregnancy and active nursing are considered absolute contraindications to BTX-A (pregnancy category C), pregnant and nursing women have been inadvertently treated with BTX-A without ill effects.<sup>[126,184]</sup> However, no studies have been specifically designed to demonstrate the safety of BTX-A in this population, nor in individuals of either sex aged  $\geq 65$  years. It is thus advisable to

**Table VI.** Absolute and relative contraindications to botulinum toxin type A (BTX-A) injections

Absolute	Allergy to any BTX-A component Infection at injection site
Relative	Pregnancy or lactation (pregnancy category C) Age $\geq 65$ y Known neuromuscular disease (e.g. myasthenia gravis, Lambert-Eaton syndrome) Inflammation at injection site Concurrent use of certain medications: aminoglycoside antibacterials, calcium channel antagonists, cholinesterase inhibitors, curare-like depolarizing agents, lincosamides, magnesium sulfate, polymyxins, quinidine, succinylcholine Unrealistic expectations or co-morbid psychiatric illnesses such as body dysmorphic disorder

postpone elective BTX-A treatment in pregnant or nursing patients; in contrast, those aged  $\geq 65$  years are treated routinely without increased concern.

Despite the high efficacy and safety rates reported for BTX-A in the management of nearly all types of focal HH, the treatment may be costly. However, patients with third-party health insurance will typically receive coverage for this approved medication in the indicated settings. Beyond the cost of the medication, most physicians charge injection fees that may range in the hundreds to over \$US1000.<sup>[185]</sup> Since BTX-A does not produce a permanent resolution of sweating symptoms, most patients require such costly repeated injections up to twice per year.

## 7. Botulinum Toxin Injection Tips

### 7.1 Minor's Iodine-Starch Test

The Minor's iodine-starch test is useful for estimating the specific areas of involvement that require treatment. In addition, it provides a qualitative means of assessing treatment response. To ensure accurate results, patients should discontinue any topical therapies (e.g. antiperspirants) 5 days prior to iodine-starch testing. In addition, iodine-starch testing should be performed prior to the application of topical anesthetics or regional nerve blocks. During the test, affected areas are first wiped with a brown-orange iodine tincture that is allowed to dry for several seconds (figure 1). The skin is then sprinkled with a starch, such as cornstarch powder. A colorimetric reaction occurs between the iodine-starch combination and eccrine sweat, resulting in a bluish-purple discoloration. This color denotes the area of excess sweating, which can subsequently be outlined with a marking pen

prior to initiating treatment. It is important to mark the area of sweating before applying ice packs, as the condensation may falsely enlarge the area. Photographs of the distribution of sweating can be taken to track the patient's response to treatment (figure 1).

## 7.2 Anesthesia

Both facial and axillary skin can be easily and painlessly injected using a 30-gauge needle without the need for anesthesia. Cryoanalgesia using ice packs may nevertheless be used to minimize any discomfort both before and after axillary or facial injections.<sup>[148]</sup> Because of the sensitivity of the palms and soles, patients with palmar or plantar HH may require regional nerve block anesthesia (i.e. wrist or ankle blocks) prior to injections. Ice cube anesthesia has proven to be of significant value in facilitating palmoplantar injections and is our current method of choice.<sup>[159]</sup> Typically, an ice cube wrapped in gauze is used to pre-cool the site of injection for about 5–10 seconds. The ice cube then precedes the injection path, thus providing time for injection while the next site is being partially anesthetized. Topical anesthesia with creams alone is rarely sufficient to reduce discomfort.<sup>[155,166]</sup> Small (30-gauge) needles can be used to inject 2% plain lidocaine to block the median, ulnar, and radial nerves (for a wrist block<sup>[186]</sup>) or the tibial and sural nerves (for an ankle block<sup>[162]</sup>). Care should be taken to keep the injection pressure slow and steady. Approximately 15–30 minutes should be allowed to pass prior to initiating Botox® injections. Regional nerve blocks are associated with a small but significant rate of complications that include vascular puncture, impaired hand dexterity, and neuropathies from repeated nerve injuries.<sup>[162,163]</sup> Wrist blocks may also lead to a reactive hyperemia that increases the tendency of bleeding from the injection site, thereby leading to loss of material from the site and a subsequent reduction in the relative effectiveness of each injection.<sup>[155]</sup> Finally, regional nerve blocks result in anesthesia that may last several hours after the procedure. Patients should therefore consider bringing along a friend or relative who can drive them home safely following the treatment.

### 7.2.1 Alternatives and Adjuncts

IVRA (Bier's block)<sup>[166,167]</sup> and vibration anesthesia<sup>[41,159,169]</sup> are relatively effective alternatives and adjuncts, respectively, to regional nerve blocks. Use of IVRA, however, requires considerable expertise as well as cardiac monitoring during the procedure because of the risk of cardiovascular and CNS toxicity.<sup>[166]</sup> Vibration anesthesia involves the application of a vibrating wand (e.g. AcuVibe™) to the skin immediately adjacent to the injection site. This technique may be used as an adjunct to regional nerve blocks if patients continue to experience discomfort following the

block.<sup>[41]</sup> Needle-free injection (e.g. using the MED-JET®) may be less effective than needle injections and may lead to bruising and crusting that can persist for weeks.<sup>[41,157,168]</sup>

## 7.3 Dilution and Injection

### 7.3.1 General Instructions

There is no standardized dosing and injection technique for the treatment of focal HH using Botox®. One vial of 100 U Botox® is generally diluted using 2–5 mL of 0.9% saline.<sup>[155]</sup> Although the product monograph recommends use of non-preserved saline, published reports demonstrate significantly less pain and no change in efficacy with preserved saline.<sup>[187,188]</sup> The precise dilution used depends on the preference of the practitioner and the number of units to be injected.

Murray et al.<sup>[41]</sup> recommend using a dilution of 3 mL per 100 U of Botox®. The contents of the vial are divided into syringes, the type and number of which depend on the area treated. For axillary HH, one 3-mL Luer-Lock® syringe (containing 100 U of Botox® diluted in 3 mL of saline) fitted with a 30-gauge needle can be used for one or both axillae, depending on the total dose required. For palmar and plantar HH, the thick skin prevents easy injection into the dermis, resulting in quicker dulling of the needles. In these cases, a 3-mL dilution should be used, with the drug being drawn up into six 0.5-mL syringes (Ultra-Fine II 30-gauge hubless insulin needle-syringe). This dilution provides 3.3 U of Botox® per 0.1-mL injection.

To prevent unnecessary dulling of the syringes, the lid and rubber stopper on the Botox® vial should be removed using a bottle opener following saline reconstitution so that the Botox® can be drawn up with the needle inside the bottle.

Generally, 0.05–0.1 mL aliquots (1.7–3.3 U) of Botox® are injected intradermally in locations spaced 1–2 cm apart within the hyperhidrotic regions.<sup>[41,155,189]</sup> Injections into the thick palmar and plantar skin produce a smaller zone of radial diffusion than injections into axillary and facial skin. Accordingly, injections should be placed slightly closer together for the palms and soles (1–1.5 cm) and slightly further apart for the axillae and face (1.5–2 cm). The surface area of the hyperhidrotic region should guide the total dose and number of injections.<sup>[94]</sup>

Botox® has a tendency to backflow from the injection tract following injection. To minimize backflow, several recommendations may be followed: (i) keep the needle bevel up; (ii) angle the needle more parallel to the skin surface; (iii) advance the needle 2 mm prior to injection; (iv) insert the needle slowly and without pressure on the plunger; (v) and wait 1–2 seconds following injection to allow time for diffusion and normalization of pressure.<sup>[41,155]</sup> This injection technique applies to treatment of all areas, but is particularly important for palmar and plantar injections.

### 7.3.2 Axillary HH

Axillary injections may be placed into the superficial fat without sacrificing efficacy or increasing the incidence of adverse events.<sup>[149]</sup> Such subcutaneous injections are less painful than the intradermal injections typically used. The appearance of a wheal following injection indicates that injections were placed at a proper depth. Injection patterns may be radial (beginning at the periphery of hair-bearing skin and spiralling towards the center of the axillary vault, or vice versa),<sup>[41,155]</sup> guided by a grid,<sup>[190]</sup> or random. Depending on the surface area of the hyperhidrotic region, 50–100 U of Botox<sup>®</sup> in 10–20 intradermal injections of 0.1–0.2 mL aliquots should be used for each axilla.<sup>[46]</sup> Studies examining BTX-A therapy specifically for axillary HH have used varying doses, typically ranging between 50 and 100 U of Botox<sup>®</sup> per axilla. Although two uncontrolled, non-comparative studies of high-dose BTX-A (200 U of Botox<sup>®</sup> in each axilla) described efficacy for as long as 29 months,<sup>[140,191]</sup> most other studies suggest little significant improvement with dosing >50 U per axilla.<sup>[56,85,144–146]</sup> One large randomized, double-blind, placebo-controlled, multicenter trial comparing 50 U and 75 U Botox<sup>®</sup> with placebo found no significant difference in the efficacy or duration of action with the higher Botox<sup>®</sup> dosage, and both doses were significantly better than placebo.<sup>[146]</sup> One report incorporated the use of hyaluronidase to facilitate spread and lower the overall dose of BTX-A used.<sup>[192]</sup>

Patients with axillary HH generally require injections every 6–12 months to maintain control of their sweating.<sup>[25,84–86,155]</sup>

### 7.3.3 Palmar and Plantar HH

Figure 2 portrays a typical injection pattern for the palms. The proper depth of injection for the palms and soles is at the junction of the dermis and subcutaneous tissue, where eccrine glands are located. Approximately 40–50 injections of 0.05–0.1 mL aliquots (1.7–3.3 U) spaced 1–1.5 cm apart should be used for each palm or sole, for a total dose of approximately 100 U of Botox<sup>®</sup>, depending on the surface area.<sup>[46,189]</sup>

The needle should be at an oblique angle, as perpendicular injections can result in significant backflow from the injection tract. Care should be taken to inject into the deep dermis, since subcutaneous injections increase the probability that the drug will diffuse into the intrinsic muscles of the hand, resulting in hand weakness. Many patients will experience some degree of hand weakness that begins 1–3 days after treatment and persists for approximately 2 weeks following treatment.<sup>[94,156]</sup> For dentists, surgeons, musicians, and other professionals who rely on the use of their hands, two options exist to minimize the impact of hand weakness on daily functioning. First, treatment may be staggered, such that each hand is treated on separate visits, with touch-up injections in the other hand, if necessary. Alternatively, treatment

may be initiated at a low dose in both hands simultaneously during the first visit. Patients should be given a choice regarding which treatment schedule they prefer after being informed about the implications associated with the available options.

The wheals produced when injecting axillary skin are not commonly found following palmar or plantar injections because of the relative stiffness of palmoplantar skin. Injections at the proper depth may nevertheless produce a small zone of visible blanching that indicates deposition of the material in the deep dermis.<sup>[155]</sup> The same technique for injections of the soles can be used, although the larger surface area may demand a greater total dose of Botox<sup>®</sup>.

Patients with palmar or plantar HH require injections every 6 months, on average, to achieve acceptable symptomatic relief.<sup>[86,170–173]</sup>

### 7.3.4 Craniofacial HH

Craniofacial HH can be treated with injections of 2–4 U of Botox<sup>®</sup> spaced every 2 cm in three horizontal rows: along the upper third of the forehead skin, along the anterior hairline, and 2 cm behind the anterior hairline.<sup>[155]</sup> Patients with craniofacial HH typically require injections every 5–6 months to maintain acceptable levels of sweating.<sup>[88,96,174]</sup>

## 8. Conclusion

Primary focal HH is a common disorder that results in considerable functional and psychosocial impairment. Patients experience symptoms for many years before presenting to their physicians.

Multiple treatment modalities currently exist, but their efficacy depends, in part, on the body area affected, the severity of the sweating, and the patient's own tolerance of and response to previous treatments. Healthcare professionals should be aware of the risks, benefits, cost, and reasonable expectations associated with the available treatment modalities. Conservative measures should generally be attempted before more invasive and irreversible options, even in patients with severe symptoms. BTX-A, although expensive, provides excellent results in safely achieving anhidrosis and improving patients' QOL for a relatively long duration. Along with aluminum chloride hexahydrate, BTX-A may be considered a first-line therapy for moderate-to-severe axillary HH, and in some cases also for excessive sweating affecting other body areas.

Although general management guidelines and algorithms for primary focal HH exist,<sup>[46,47,58–60]</sup> healthcare professionals should make an attempt to tailor treatment options to each patient individually, taking risks, benefits, cost, and convenience into account.

## Acknowledgments

No sources of funding were used to assist in the preparation of this review. Nowell Solish has received honoraria from Allergan for speaking on the use of botulinum toxin for hyperhidrosis. The other authors have no conflicts of interest that are directly relevant to the content of this review.

## References

- Iwase S, Ikeda T, Kitazawa H, et al. Altered response in cutaneous sympathetic outflow to mental and thermal stimuli in primary palmoplantar hyperhidrosis. *J Auton Nerv Syst* 1997; 64: 65-73
- Adar R, Kurchin A, Zweig A, et al. Palmar hyperhidrosis and its surgical treatment. *Ann Surg* 1977; 186 (1): 34-41
- Kreyden OP, Schmid-Grendelmeier P, Burg G. Idiopathic localized unilateral hyperhidrosis. *Arch Dermatol* 2001; 137: 1622-5
- Hamm H, Naumann M, Kowalski JW, et al. Primary focal hyperhidrosis: disease characteristics and functional impairment. *Dermatology* 2006; 212: 343-53
- Lear W, Kessler E, Solish N, et al. An epidemiological study of hyperhidrosis. *Dermatol Surg* 2007; 33: S69-75
- Strutton DR, Kowalski JW, Glaser DA, et al. US prevalence of hyperhidrosis and impact on individuals with axillary hyperhidrosis: results from a national survey. *J Am Acad Dermatol* 2004; 51: 241-8
- Atkins JL, Butler PEM. Hyperhidrosis: a review of current management. *Plast Reconstr Surg* 2001; 110 (1): 222-8
- Haider A, Solish N. Hyperhidrosis: an approach to diagnosis and management. *Dermatol Nurs* 2004; 16 (6): 515-23
- Leung AKC, Chan PYH, Choi MCK. Hyperhidrosis. *Int J Dermatol* 1999; 38: 561-7
- Stolman LP. Treatment of hyperhidrosis. *Curr Ther* 1998; 16: 853-67
- Haider A, Solish N, Lowe NJ. Management of hyperhidrosis. In: Carruthers A, Carruthers J, editors. *Procedures in cosmetic dermatology series: Botulinum toxin*. Philadelphia (PA): Saunders, 2004: 83-92
- Christophers E, Kruger G. Psoriasis. In: Fitzpatrick TB, Eisen AZ, Wolff K, editors. *Dermatology in general medicine*. 3rd ed. New York: McGraw-Hill, 1987: 461-91
- Glaser DA, Kessler E. A demographical analysis of hyperhidrosis [abstract]. *J Am Acad Dermatol* 2007; 56 (2): AB46
- Mosek A, Korczyn A. Hyperhidrosis in palms and soles. In: Korczyn A, editor. *Handbook of autonomic nervous system dysfunction*. New York: Marcel Dekker, 1995: 167-77
- Hamm H, Naumann M, Kozma C, et al. Primary focal hyperhidrosis: comparison of functional impairment, health-related quality of life, and medical history across a large cohort of patients by focal location and nonhyperhidrotic controls [abstract]. *J Am Acad Dermatol* 2005; 52 (3): 57
- Kaufmann H, Saadia D, Polin C, et al. Primary hyperhidrosis: evidence for autosomal dominant inheritance. *Clin Auton Res* 2003; 13: 96-8
- Draeos ZD. Antiperspirants and the hyperhidrosis patient. *Dermatol Ther* 2001; 14: 220-4
- Hölzle E. Topical pharmacological treatment. *Curr Probl Dermatol* 2002; 30: 30-43
- Filosto M, Bertolasi L, Fincati E, et al. Axillary injection of botulinum A toxin in a patient with muscle cramps associated with severe axillary hyperhidrosis. *Acta Neurol Belg* 2001; 101: 121-3
- Duller P, Gentry WD. Use of biofeedback in treating chronic hyperhidrosis: a preliminary report. *Br J Dermatol* 1980; 103: 143-7
- Elgart ML, Fuchs G. Tapwater iontophoresis in the treatment of hyperhidrosis: use of the Drionic device. *Int J Dermatol* 1987; 26 (3): 194-7
- Odia S, Vocks E, Rakoski J, et al. Successful treatment of dyshidrotic hand eczema using tap water iontophoresis with pulsed direct current. *Acta Derm Venereol* 1996; 76: 472-4
- Wollina U, Uhlemann C, Elstermann D, et al. Therapy of hyperhidrosis with tap water iontophoresis: positive effect on healing time and lack of recurrence in hand-foot eczema. *Hautarzt* 1998; 49 (2): 109-13
- Benohanian A. Antiperspirants and deodorants. *Clin Dermatol* 2001; 19: 398-405
- Glogau RG. Botulinum A neurotoxin for axillary hyperhidrosis: no sweat Botox. *Dermatol Surg* 1998; 24: 817-9
- Glogau RG. Treatment of palmar hyperhidrosis with botulinum toxin. *Semin Cutan Med Surg* 2001; 20 (2): 101-8
- Weber A, Heger S, Sinkgraven R, et al. Psychosocial aspects of patients with focal hyperhidrosis: marked reduction of social phobia, anxiety and depression and increased quality of life after treatment with botulinum toxin A. *Br J Dermatol* 2005; 114: 342-5
- Cina CS, Clase CM. The Illness Intrusiveness Rating Scale: a measure of severity in individuals with hyperhidrosis. *Qual Life Res* 1999; 8: 693-8
- Spalding JR, Kowalski JW, Lee J, et al. Effect of pharmacologic treatment on dermatologic-specific quality of life (QOL): a comparison of botulinum toxin type-A (BT-A) for primary focal hyperhidrosis (HH) to medical treatments for other dermatological diseases [abstract]. *J Am Acad Dermatol* 2004; 50 (3): 51
- Swartling C, Naver H, Lindberg M. Botulinum A toxin improves life quality in severe primary focal hyperhidrosis. *Eur J Neurol* 2001; 8: 247-52
- Naumann M, Lowe NJ, Kumar CR, et al. Botulinum toxin type A is a safe and effective treatment for axillary hyperhidrosis over 16 months. *Arch Dermatol* 2003; 139: 731-6
- Naumann M, Hamm H, Lowe NJ. Effect of botulinum toxin type A on quality of life measures in patients with excessive axillary sweating: a randomized controlled trial. *Br J Dermatol* 2002; 147: 1218-26
- Campanati A, Penna L, Guzzo T, et al. Quality-of-life assessment in patients with hyperhidrosis before and after treatment with botulinum toxin: results of an open-label study. *Clin Ther* 2003; 25: 298-308
- Solish N, Benohanian A, Kowalski JW. Prospective open-label study of botulinum toxin type A in patients with axillary hyperhidrosis: effects on functional impairment and quality of life. *Dermatol Surg* 2005; 31 (4): 405-13
- Sato K, Kang WH, Saga K, et al. Biology of sweat glands and their disorders: I. Normal sweat gland function. *J Am Acad Dermatol* 1989; 20: 537-63
- Wilke K, Martin A, Terstegen L, et al. A short history of sweat gland biology. *Int J Cosmet Sci* 2007; 29: 169-79
- Kreyden OP, Scheidegger EP. Anatomy of the sweat glands, pharmacology of botulinum toxin, and distinctive syndromes associated with hyperhidrosis. *Clin Dermatol* 2004; 22: 40-4
- Sato K, Kang WH, Saga K, et al. Biology of sweat glands and their disorders: II. Disorders of sweat gland function. *J Am Acad Dermatol* 1989; 20: 713-26
- Bovell DL, Clunes MT, Elder HY, et al. Ultrastructure of the hyperhidrotic eccrine sweat gland. *Br J Dermatol* 2001; 145: 298-301
- Manca D, Valls-Sole J, Callejas MA. Excitability recovery curve of the sympathetic skin response in healthy volunteers and patients with palmar hyperhidrosis. *Clin Neurophysiol* 2000; 111: 1767-70
- Murray CA, Cohen JL, Solish N. Treatment of focal hyperhidrosis. *J Cutan Med Surg* 2007; 11 (2): 67-77
- Shih C-J, Lin MT. Thermoregulatory sweating in palmar hyperhidrosis before and after upper thoracic sympathectomy. *J Neurosurg* 1979; 50: 88-94
- Shih C-J, Wu J-J, Lin M-T. Autonomic dysfunction in palmar hyperhidrosis. *J Auton Nerv Syst* 1983; 8: 33-43
- Lin TK, Chee ECY, Chen HJ, et al. Abnormal sympathetic skin response in patients with palmar hyperhidrosis. *Muscle Nerve* 1995; 18 (8): 917-9
- Birner P, Heinzel H, Schindl M, et al. Cardiac autonomic function in patients suffering from primary focal hyperhidrosis. *Eur Neurol* 2000; 44 (2): 112-6
- Hornberger J, Grimes K, Naumann M, et al. Recognition, diagnosis, and treatment of primary focal hyperhidrosis. *J Am Acad Dermatol* 2004; 51 (2): 274-86
- Solish N, Bertucci V, Dansereau A, et al. A comprehensive approach to the recognition, diagnosis, and severity-based treatment of focal hyperhidrosis:

- recommendations of the Canadian Hyperhidrosis Advisory Committee. *Dermatol Surg* 2007; 33: 908-23
48. Krogstad A-L, Piechnik K. Are patients better than the laboratory in assessing sweating? Validation study. *Dermatol Surg* 2005; 31 (11): 1434-9
  49. Vadoud-Seyedi J, Simonart T. Treatment of axillary hyperhidrosis with botulinum toxin type A reconstituted in lidocaine or in normal saline: a randomized, side-by-side, double-blind study. *Br J Dermatol* 2007; 156: 986-9
  50. Solish N, Benohanian A, Kowalski JW. Prospective open-label study of botulinum toxin type A in patients with axillary hyperhidrosis: effects on functional impairment and quality of life. *Dermatol Surg* 2005; 31 (4): 405-13
  51. Kowalski JW, Eadie N, Daggett S, et al. Validity and reliability of the Hyperhidrosis Disease Severity Scale (HDSS). Poster presented at the 62nd Annual Meeting of the American Academy of Dermatology; 2004 Feb 6-10; Washington, DC
  52. Krogstad A-L, Skymne A, Pegenius G, et al. Evaluation of objective methods to diagnose palmar hyperhidrosis and monitor effects of botulinum toxin treatment. *Clin Neurophysiol* 2004; 115: 1909-16
  53. Stefaniak T, Vingerhoets A, Proczko-Markuszczyńska M. The importance of quantitative evaluation in the follow-up after sympathectomy for primary hyperhidrosis. *Clin Auton Res* 2007; 17: 122-3
  54. Rompel R, Scholz S. Subcutaneous curettage vs. injection of botulinum toxin A for treatment of axillary hyperhidrosis. *J Eur Acad Dermatol Venereol* 2001; 15: 207-11
  55. Swinehart JM. Treatment of axillary hyperhidrosis: combination of the starch-iodine test with the tumescent liposuction technique. *Dermatol Surg* 2000; 26: 392-6
  56. Naumann M, Lowe NJ. Botulinum toxin type A in treatment of bilateral primary axillary hyperhidrosis: randomised, parallel group, double blind, placebo controlled trial. *BMJ* 2001; 323: 596-9
  57. Haider A, Solish N. Focal hyperhidrosis: diagnosis and management. *Can Med Assoc J* 2005; 172 (1): 69-75
  58. Cheung JS, Solomon BA. Disorders of sweat glands: hyperhidrosis. Unapproved treatments. *Clin Dermatol* 2002; 20: 638-42
  59. Lowe NJ, Campanati A, Bodokh I, et al. The place of botulinum toxin type A in the treatment of focal hyperhidrosis. *Br J Dermatol* 2004; 151: 1115-22
  60. Benohanian A, Boudjikianian A, Paylan Y. Palmar and plantar hyperhidrosis: a practical management algorithm. *Therapy* 2007; 4 (3): 279-83
  61. Scholes KT, Crow KD, Ellis JP, et al. Axillary hyperhidrosis treated with alcoholic solution of aluminum chloride hexahydrate. *BMJ* 1978; 2: 84-5
  62. Reifenrath WG, Prystowsky SD, Nonomura JH, et al. Topical glutaraldehyde: percutaneous penetration and skin irritation. *Arch Dermatol Res* 1985; 277 (3): 242-4
  63. Juhlin L, Hansson H. Topical glutaraldehyde for plantar hyperhidrosis. *Br J Dermatol* 1968; 97: 327-30
  64. Grice K. Treatment of hyperhidrosis. *Clin Exp Dermatol* 1982; 7: 183-8
  65. Juhlin L, Hansson H. Topical glutaraldehyde for plantar hyperhidrosis. *Arch Dermatol* 1968; 97: 327-30
  66. Grimalt R, Tordera PD, Callejas MA. Topical atropine sulfate for the treatment of axillary hyperhidrosis. *J Cosmet Dermatol* 2006; 5: 294-6
  67. Madan V, Beck MH. Urinary retention caused by topical glycopyrrolate for hyperhidrosis. *Br J Dermatol* 2006; 155: 634-5
  68. Macmillan FS, Reller HH, Synder FH. The antiperspirant action of topically applied anticholinergics. *J Invest Derm* 1964; 43: 363-77
  69. Agren-Jonsson S, Magnusson S. Sensitization to propantheline bromide, trichlorocarbanilide and propylene glycol in an antiperspirant. *Contact Dermat* 1976; 2 (2): 79-80
  70. Luh JY, Blackwell TA. Craniofacial hyperhidrosis successfully treated with topical glycopyrrolate. *South Med J* 2002; 95 (7): 756-8
  71. Seukeran DC, Highet AS. The use of topical glycopyrrolate in the treatment of hyperhidrosis. *Clin Exp Dermatol* 1998; 23: 204-5
  72. Hays LL. The Frey syndrome: a review and double blind evaluation of the topical use of a new anticholinergic agent. *Laryngoscope* 1978; 88: 1796-824
  73. Atkin SL, Brown PM. Treatment of diabetic gustatory sweating with topical glycopyrrolate cream. *Diabet Med* 1996; 13 (5): 493-4
  74. Shaw JE, Abbott CA, Tindle K, et al. A randomised controlled trial of topical glycopyrrolate, the first specific treatment for diabetic gustatory sweating. *Diabetologia* 1997; 40 (3): 299-301
  75. Kim WO, Kil HK, Yoon DM, et al. Treatment of compensatory gustatory hyperhidrosis with topical glycopyrrolate. *Yonsei Med J* 2003; 44 (4): 579-82
  76. Juhlin L, Evers H, Broberg F. Inhibition of hyperhidrosis by topical application of a local anesthetic composition. *Acta Derm Venereol* 1979; 59 (6): 556-9
  77. Abell E, Morgan K. The treatment of idiopathic hyperhidrosis by glycopyrronium bromide and tap water iontophoresis. *Br J Dermatol* 1974; 91: 87-91
  78. Dolianitiis C, Scarff CE, Kelly J, et al. Iontophoresis with glycopyrrolate for the treatment of palmo-plantar hyperhidrosis. *Australas J Dermatol* 2004; 45: 208-12
  79. Sloan JB, Soltani K. Iontophoresis in dermatology: a review. *J Am Acad Dermatol* 1986; 15 (4): 671-84
  80. Hölzle E, Alberti N. Long term efficacy and side effects of tap water iontophoresis for palmo-plantar hyperhidrosis: the usefulness of home therapy. *Dermatologica* 1987; 175: 126-35
  81. Shrivastava SN, Singh G. Tap water iontophoresis in palmo-plantar hyperhidrosis. *Br J Dermatol* 1977; 96: 189-95
  82. Mirakhor RK, Dundee JW, Jones CJ. Evaluation of the anticholinergic actions of glycopyrronium bromide. *Br J Clin Pharmacol* 1978; 5: 77-84
  83. Bajaj V, Langtry JAA. Use of oral glycopyrronium bromide in hyperhidrosis. *Br J Dermatol* 2007; 157: 118-21
  84. Bushara KO, Park DM, Jones JC, et al. Botulinum toxin: a possible new treatment for axillary hyperhidrosis. *Clin Exp Dermatol* 1996; 21: 276-8
  85. Heckmann M, Ceballos-Baumann AO, Plewig G. Botulinum toxin A for axillary hyperhidrosis (excessive sweating). *N Engl J Med* 2001; 344 (7): 488-93
  86. Naumann M, Bergmann I, Hamm H, et al. Focal hyperhidrosis: effective treatment with intracutaneous botulinum toxin. *Arch Dermatol* 1998; 134: 301-4
  87. Naver H, Swartling C, Aquilonius SM. Palmar and axillary hyperhidrosis treated with botulinum toxin: one-year clinical follow-up. *Eur J Neurol* 2000; 7: 55-62
  88. Tan SR, Solish N. Long-term efficacy and quality of life in the treatment of focal hyperhidrosis with botulinum toxin A. *Dermatol Surg* 2002; 28 (6): 495-9
  89. Shelley WB, Talanin NY, Shelley ED. Botulinum toxin therapy for palmar hyperhidrosis. *J Am Acad Dermatol* 1998; 38: 227-9
  90. Solomon BA, Hayman R. Botulinum toxin type A therapy for palmar and digital hyperhidrosis. *J Am Acad Dermatol* 2000; 42 (6): 1026-9
  91. Schneider P, Binder M, Berger T, et al. Botulinum A toxin injection in focal hyperhidrosis. *Br J Dermatol* 1996; 134 (6): 1160-1
  92. Naumann M, Flachenecker P, Brocker EB, et al. Botulinum toxin for palmar hyperhidrosis. *Lancet* 1997; 349: 252
  93. Holmes S, Mann C. Botulinum toxin in the treatment of palmar hyperhidrosis. *J Am Acad Dermatol* 1998; 39: 1040-1
  94. Saadia D, Voustantiokou A, Wang AK, et al. Botulinum toxin type A in primary palmar hyperhidrosis. *Neurology* 2001; 57: 2095-9
  95. Schneider P, Binder M, Auff E, et al. Double-blind trial of botulinum A toxin for the treatment of focal hyperhidrosis of the palms. *Br J Dermatol* 1997; 136: 548-52
  96. Boger A, Herath H, Rompel R, et al. Botulinum toxin for treatment of craniofacial hyperhidrosis. *J Neurol* 2000; 415: 857-61
  97. Trindade de Almeida AR, Marques E, de Almeida J, et al. Pilot study comparing the diffusion of two formulations of botulinum toxin type A in patients with forehead hyperhidrosis. *Dermatol Surg* 2007; 33: S37-43
  98. Lowe NJ, Yamauchi PS, Lask GP, et al. Efficacy and safety of botulinum toxin type A in the treatment of palmar hyperhidrosis: a double-blind, randomized, placebo-controlled study. *Dermatol Surg* 2002; 28 (9): 822-7
  99. Wu WH, Ma S, Lin JT, et al. Surgical treatment of axillary osmidrosis: an analysis of 343 cases. *Plast Reconstr Surg* 1994; 94 (2): 288-94

100. Endo T, Nakayama Y. Surgical treatment of axillary osmidrosis. *Ann Plast Surg* 1993; 30: 136-9
101. Yoshikata R, Yanai A, Takei T, et al. Surgical treatment of axillary osmidrosis. *Br J Plast Surg* 1990; 43: 483-5
102. Ou LF, Yan RS, Chen IC, et al. Treatment of axillary bromhidrosis with superficial liposuction. *Plast Reconstr Surg* 1998; 102: 1479-85
103. Park S. Very superficial ultrasound-assisted lipoplasty for the treatment of axillary osmidrosis. *Aesth Plast Surg* 2004; 24 (4): 275-9
104. Tsai RY, Lin JY. Experience of tumescent liposuction in the treatment of osmidrosis. *Dermatol Surg* 2001; 27: 446-8
105. Chung S, Yoo WM, Park YG, et al. Ultrasonic surgical aspiration with endoscopic confirmation for osmidrosis. *Br J Plast Surg* 2000; 53 (3): 212-4
106. Tung TC. Endoscopic shaver with liposuction for treatment of axillary osmidrosis. *Ann Plast Surg* 2001; 46 (4): 400-4
107. Bechara FG, Sand M, Tomi NS, et al. Repeat liposuction-curettage treatment of axillary hyperhidrosis is safe and effective. *Br J Dermatol* 2007; 157: 739-43
108. Tsai RY. Treatment of excessive axillary sweat syndromes (hyperhidrosis, osmidrosis, bromhidrosis) with liposuction. In: Shiffman MA, Di Giuseppe A, editors. *Liposuction: principles and practice*. Berlin: Springer; 2006: 496-501
109. Boni R. Tumescent suction curettage in the treatment of axillary hyperhidrosis: experience in 63 patients. *Dermatology* 2006; 213 (3): 215-7
110. Lee D, Cho SH, Kim YC, et al. Tumescent liposuction with dermal curettage for treatment of axillary osmidrosis and hyperhidrosis. *Dermatol Surg* 2006; 32: 505-11
111. Perng CK, Yeh FL, Ma H, et al. Is the treatment of axillary osmidrosis with liposuction better than open surgery? *Plast Reconstr Surg* 2003; 114: 93-7
112. Reisfeld R, Nguyen R, Pnini A. Endoscopic thoracic sympathectomy for hyperhidrosis: experience with both cauterization and clamping methods. *Surg Laparosc Endosc Percutan Techn* 2002; 12: 255-67
113. Wilkinson H. Radiofrequency percutaneous upper-thoracic sympathectomy. *N Engl J Med* 1984; 311: 43-6
114. Chou SH, Kao EL, Lin CC, et al. The outcome of ganglion clipping in hyperhidrosis and blushing. *Clin Auton Res* 2006; 16: 240-2
115. Dumont P, Denoyer A, Robin P. Long-term results for thoracoscopic sympathectomy for hyperhidrosis. *Ann Thorac Surg* 2004; 78: 1801-7
116. Neumayer C, Panhofer P, Jakesz R, et al. Surgical treatment of facial hyperhidrosis and blushing: mid-term results after endoscopic sympathetic block and review of the literature. *Eur Surg* 2005; 37 (3): 127-36
117. Moya J, Ramos R, Morera R, et al. Thoracic sympathectomy for primary hyperhidrosis: a review of 918 procedures. *Surg Endosc* 2006; 20: 598-602
118. Furlan AD, Mailis A, Papagapiou M. Are we paying a high price for surgical sympathectomy? A systematic literature review of late complications. *J Pain* 2000; 1 (4): 245-57
119. Gossot D, Galetta D, Pascal A, et al. Long-term results of endoscopic thoracic sympathectomy for upper limb hyperhidrosis. *Ann Thorac Surg* 2003; 75: 1075-9
120. Zacherl J, Huber ER, Imhof M, et al. Long-term results of 630 thoracoscopic sympathectomies for primary hyperhidrosis: the Vienna experience. *Eur J Surg* 1998; 164 Suppl. 580: 43-6
121. Leseche G, Castier Y, Thabut G, et al. Endoscopic transthoracic sympathectomy for upper limb hyperhidrosis: limited sympathectomy does not reduce postoperative compensatory sweating. *J Vasc Surg* 2003; 37 (1): 124-8
122. Simpson LL. The origin, structure, and pharmacological activity of botulinum toxin. *Pharmacol Rev* 1981 Sep; 33 (3): 155-88
123. Simonetta Moreau M, Cauhepe C, Magues JP, et al. A double-blind, randomized, comparative study of Dysport vs. Botox in primary palmar hyperhidrosis. *Br J Dermatol* 2003; 149: 1041-5
124. Krack P, Deuschl G, Benecke R, et al. Dose standardization of botulinum toxin. *Mov Disord* 1998; 13 (4): 749-51
125. Talarico-Filho S, do Nascimento MM, de Macedo FS, et al. A double-blind, randomized, comparative study of two type A botulinum toxins in the treatment of primary axillary hyperhidrosis. *Dermatol Surg* 2007; 33: S44-50
126. Klein AW. Contraindications and complications with the use of botulinum toxin. *Clin Dermatol* 2004; 22: 66-75
127. Swartling C, Naver H, Pihl-Lundin I, et al. Sweat gland morphology and periglandular innervation in essential palmar hyperhidrosis before and after treatment with intradermal botulinum toxin. *J Am Acad Dermatol* 2004; 51: 739-45
128. Product monograph: Botox (botulinum toxin type A) purified neurotoxin complex. Irvine (CA): Allergan, Inc., 2004
129. Moreau SM, Cauhepe C, Magues JP, et al. A double-blind, randomized, comparative study of Dysport vs. Botox in primary palmar hyperhidrosis. *Br J Dermatol* 2003; 149: 1041-5
130. Baumann L, Slezinger A, Halem M, et al. Double-blind, randomized, placebo-controlled pilot study of the safety and efficacy of Myobloc (botulinum toxin type B) for the treatment of palmar hyperhidrosis. *Dermatol Surg* 2005; 31 (3): 263-70
131. Baumann L, Slezinger A, Halem M, et al. Pilot study of the safety and efficacy of Myobloc (botulinum toxin type B) for treatment of axillary hyperhidrosis. *Int J Dermatol* 2005; 44: 418-24
132. Dressler D, Saberi FA, Benecke R. Botulinum toxin type B for treatment of axillary hyperhidrosis. *J Neurol* 2002; 249: 1729-32
133. Hecht MJ, Birklein F, Winterholler M. Successful treatment of axillary hyperhidrosis with very low doses of botulinum toxin B: a pilot study. *Arch Dermatol Res* 2004; 295: 318-9
134. Nelson L, Bachoo P, Holmes J. Botulinum toxin type B: a new therapy for axillary hyperhidrosis. *Br J Plast Surg* 2005; 58: 228-32
135. Lim ECH, Seet RCS, Chow A, et al. Topical botulinum toxin to treat hyperhidrosis? No sweat! *Med Hypotheses* 2006; 67: 27-32
136. Glogau RG. Topically applied botulinum toxin type A for the treatment of primary axillary hyperhidrosis: results of a randomized, blinded, vehicle-controlled study. *Dermatol Surg* 2007; 33 (1 Spec No.): S76-80
137. Kavanagh GM, Oh C, Shams K. Botox delivery by iontophoresis. *Br J Dermatol* 2004; 15: 1093-5
138. Odderson IR. Long-term quantitative benefits of botulinum toxin type A in the treatment of axillary hyperhidrosis. *Dermatol Surg* 2002; 28 (6): 480-3
139. Schnider P, Binder M, Kittler H, et al. A randomized, double-blind, placebo-controlled trial of botulinum A toxin for severe axillary hyperhidrosis. *Br J Dermatol* 1999; 140: 677-80
140. Wollina U, Karamfilov T, Konrad H. High-dose botulinum toxin type A therapy for axillary hyperhidrosis markedly prolongs the relapse-free interval. *J Am Acad Dermatol* 2002; 46 (4): 536-40
141. Salmanpoor R, Rahmanian MJ. Treatment of axillary hyperhidrosis with botulinum-A toxin. *Int J Dermatol* 2002; 41: 428-30
142. Whatling PJ, Collin J. Botulinum toxin injection is an effective treatment for axillary hyperhidrosis. *Br J Surg* 2001; 88: 814-5
143. Heckmann M, Breit S, Ceballos-Baumann AO, et al. Side-controlled intradermal injection of botulinum toxin A in recalcitrant axillary hyperhidrosis. *J Am Acad Dermatol* 1999; 41: 987-90
144. Heckmann M, Plewig G. Low-dose efficacy of botulinum toxin A for axillary hyperhidrosis. *Arch Dermatol* 2005; 141: 1255-9
145. Galadari I, Alkaabi J. Botulinum toxin in the treatment of axillary hyperhidrosis. *Skinmed* 2003; 2: 209-11
146. Lowe NJ, Glaser DA, Eadie N, et al. Botulinum toxin type A in the treatment of primary axillary hyperhidrosis: a 52-week multicenter double-blind, randomized, placebo-controlled study of efficacy and safety. *J Am Acad Dermatol* 2007; 56 (4): 604-11
147. Lowe PL, Cerdan-Sanz S, Lowe NJ. Botulinum toxin type A in the treatment of bilateral primary axillary hyperhidrosis: efficacy and duration with repeated treatments. *Dermatol Surg* 2003; 29 (5): 545-8
148. Bechara FG, Sand M, Altmeyer P, et al. Skin cooling for botulinum toxin A injection in patients with focal axillary hyperhidrosis. *Ann Plast Surg* 2007; 58 (3): 299-302

149. Pearson IC, Cliff S. Botulinum toxin type A treatment for axillary hyperhidrosis: a comparison of intradermal and subcutaneous injection techniques. *Br J Dermatol* 2004; 151 Suppl. 68: 95
150. Krogstad A-L, Skymne A, Pegenius G, et al. No compensatory sweating after botulinum toxin treatment of palmar hyperhidrosis. *Br J Dermatol* 2005; 152: 329-33
151. Naumann M, Hamm H, Kinkelin I, et al. Botulinum toxin type A in the treatment of focal, axillary and palmar hyperhidrosis and other hyperhidrotic conditions. *Eur J Neurol* 1999; 6 Suppl. 4: S111-5
152. Perez-Bernal AM, Avalos-Peralta P, Moreno-Ramirez D, et al. Treatment of palmar hyperhidrosis with botulinum toxin type A: 44 months of experience. *J Cosmet Dermatol* 2005; 4: 163-6
153. Wollina U, Karamfilov T. Botulinum toxin A for palmar hyperhidrosis. *J Eur Acad Dermatol Venereol* 2001; 15: 555-8
154. Caro S, Brin M, Kaufmann H. Treatment of palmar hyperhidrosis with botulinum toxin. *Clin Auton Res* 1996; 6: 301
155. Glogau RG. Hyperhidrosis and botulinum toxin A: patient selection and techniques. *Clin Dermatol* 2004; 22: 45-52
156. Swartling C, Farnstrand C, Abt G, et al. Side-effects of intradermal injections of botulinum A toxin in the treatment of palmar hyperhidrosis: a neurophysiological study. *Eur J Neurol* 2001; 8: 451-6
157. Naumann M, Bergmann I, Hofmann U, et al. Botulinum toxin for focal hyperhidrosis: technical considerations and improvements in application. *Br J Dermatol* 1998; 139 (6): 1123-4
158. O'Riordan JM, Fitzgerald E, Gowing C, et al. Topical local anaesthetic (tetracaine) reduces pain from botulinum toxin injections for axillary hyperhidrosis. *Br J Surg* 2006; 93: 713-4
159. Smith KC, Comite SL, Storwick GS. Ice minimizes discomfort associated with injection of botulinum toxin type A for the treatment of palmar and plantar hyperhidrosis. *Dermatol Surg* 2007; 33 (1 Spec No.): S88-91
160. Baumann L, Frankel S, Welsh E, et al. Cryoanalgesia with dichlorotetrafluoroethane lessens the pain of botulinum toxin injections for the treatment of palmar hyperhidrosis. *Dermatol Surg* 2003; 29 (10): 1057-60
161. Kontochristopoulos G, Gregoriou S, Zakapoulou N, et al. Cryoanalgesia with dichlorotetrafluoroethane spray versus ice packs in patients treated with botulinum toxin-A for palmar hyperhidrosis: self-controlled study. *Dermatol Surg* 2006; 32: 873-4
162. Fujita M, Mann T, Mann O, et al. Surgical pearl: use of nerve blocks for botulinum toxin treatment of palmar-plantar hyperhidrosis. *J Am Acad Dermatol* 2001; 45: 587-9
163. Hayton MJ, Stanley JK, Lowe NJ. A review of peripheral nerve blockade as local anaesthesia in the treatment of palmar hyperhidrosis. *Br J Dermatol* 2003; 149: 447-51
164. Trindade de Almeida AR, Kadunc BV, Martins de Oliveira EM. Improving botulinum toxin therapy for palmar hyperhidrosis: wrist block and technical considerations. *Dermatol Surg* 2001; 27 (1): 34-6
165. Campanati A, Lagalla G, Penna L, et al. Local neural block at the wrist for treatment of palmar hyperhidrosis with botulinum toxin: technical improvements. *J Am Acad Dermatol* 2004; 51: 345-8
166. Blaheta HJ, Vollert B, Zuder D, et al. Intravenous regional anesthesia (Bier's block) for botulinum toxin therapy of palmar hyperhidrosis is safe and effective. *Dermatol Surg* 2002; 28: 666-72
167. Vollert B, Blaheta HJ, Moehrl R, et al. Intravenous regional anaesthesia for treatment of palmar hyperhidrosis with botulinum toxin type A. *Br J Dermatol* 2001; 144 (3): 632-3
168. Benohanian A. Surgical pearl: use of needle-free anesthesia in the treatment of palmar hyperhidrosis with botulinum A toxin. *J Am Acad Dermatol* 2005; 52: 1073-4
169. Smith KC, Comite SL, Balasubramanian S, et al. Vibration anesthesia: a non-invasive method of reducing discomfort prior to dermatologic procedures. *Dermatol Online J* 2004; 10 (2): 1
170. Vadoud-Seyedi J. Treatment of plantar hyperhidrosis with botulinum toxin type A. *Int J Dermatol* 2004; 43: 969-71
171. Vadoud-Seyedi J, Simonart T, Heenen M. Treatment of plantar hyperhidrosis with Dermojet injections of botulinum toxin. *Dermatology* 2000; 201: 179
172. Sevim S, Dogu O, Kaleagasi H. Botulinum toxin-A therapy for palmar and plantar hyperhidrosis. *Acta Neurol Belg* 2002; 102: 167-70
173. Campanati A, Bernardini ML, Gesuita R, et al. Plantar focal idiopathic hyperhidrosis and botulinum toxin: a pilot study. *Eur J Dermatol* 2007; 17 (1): 52-4
174. Kinkelin I, Hund M, Naumann M, et al. Effective treatment of frontal hyperhidrosis with botulinum toxin A. *Br J Dermatol* 2000; 143: 824-7
175. Barankin B, Wasel N. Treatment of inguinal hyperhidrosis with botulinum toxin type A. *Int J Dermatol* 2006; 45: 985-6
176. Bechara FG, Sand M, Achenbach RK, et al. Focal hyperhidrosis of the anal fold: successful treatment with botulinum toxin A. *Dermatol Surg* 2007; 33: 924-7
177. Wollina U, Konrad H. Botulinum toxin A in anal fissures: a modified technique. *J Eur Acad Dermatol Venereol* 2002; 16: 469-71
178. Pena NA, Alam M, Yoo SS. Complications with the use of botulinum toxin type A for cosmetic applications and hyperhidrosis. *Semin Cutan Med Surg* 2007; 26: 29-33
179. Emmerson J. Botulinum toxin for spasmodic torticollis in a patient with myasthenia gravis. *Mov Disord* 1994; 9: 367
180. Iwase T, Iwase C. Systemic effect of local and small-dose botulinum toxin injection to unmask subclinical myasthenia gravis. *Graefes Arch Clin Exp Ophthalmol* 2006; 244: 415-6
181. Erbguth F, Claus D, Engelhardt A, et al. Systemic effect of local botulinum toxin injections unmasks subclinical Lambert-Eaton myasthenic syndrome. *J Neurol Neurosurg Psychiatry* 1993; 56 (11): 1235-6
182. Goncalves MR, Barbosa ER, Zambon AA, et al. Treatment of cervical dystonia with botulinum toxin in a patient with myasthenia gravis. *Arg Neuropsiquiatr* 1999; 57 (3A): 683-5
183. Fasano A, Bentivoglio AR, Ialongo T, et al. Treatment with botulinum toxin in a patient with myasthenia gravis and cervical dystonia. *Neurology* 2005; 64 (12): 2155-6
184. Scott AB. Clostridial toxins as therapeutic agents. In: Simpson LL, editor. *Botulinum neurotoxin and tetanus toxin*. New York: Academic Press, 1989: 399-412
185. Thomas I, Brown J, Vafaie J, et al. Palmoplantar hyperhidrosis: a therapeutic challenge. *Am Fam Physician* 2004; 69 (5): 1117-20
186. de Almeida ART, Kadunc BV, de Oliveira EMM. Improving botulinum toxin therapy for palmar hyperhidrosis: wrist block and technical considerations. *Dermatol Surg* 2001; 27 (1): 34-6
187. Kwiat DM, Bersani TA, Bersani A. Increased patient comfort utilizing botulinum toxin type A reconstituted with preserved versus nonpreserved saline. *Ophthalm Plast Reconstr Surg* 2004; 20 (3): 186-9
188. van Laborde S, Dover JS, Moore M, et al. Reduction in injection pain with botulinum toxin type B further diluted using saline with preservative: a double-blind, randomized controlled trial. *J Am Acad Dermatol* 2003; 48 (6): 875-7
189. Glaser DA, Hebert AA, Pariser DM, et al. Palmar and plantar hyperhidrosis: best practice recommendations. *Cutis* 2007; 79 Suppl. 5: 18-28
190. Jain S. A new multiple site marking grid for botulinum toxin application in the treatment of axillary hyperhidrosis. *Br J Dermatol* 2006; 154: 375-6
191. Karamfilov T, Konrad H, Karte K, et al. Lower relapse rate of botulinum toxin A therapy for axillary hyperhidrosis by dose increase. *Arch Dermatol* 2000; 136: 487-90
192. Goodman G. Diffusion and short-term efficacy of botulinum toxin A after the addition of hyaluronidase and its possible application for the treatment of axillary hyperhidrosis. *Dermatol Surg* 2003; 29: 533-8

Correspondence: Christian A. Murray, Division of Dermatology, University of Toronto, Women's College Hospital, 76 Grenville Street, Room 842, Toronto, ON, Canada M5S 1B2.