

Treatment of Palmar Hyperhidrosis With Botulinum Toxin

Richard G. Glogau, MD

Excessive sweating of the palms, axillae, and soles can be managed with intradermal injections of botulinum toxin as an alternative to more aggressive surgical therapies such as sympathectomy and less effective techniques including topical antiperspirants. The dosage and injection techniques can be optimized to provide several months of freedom from this troubling disorder.
Copyright © 2001 by W.B. Saunders Company

FOCAL IDIOPATHIC and episodic eccrine sweating of the palms and soles troubles afflicted individuals with a social curse that can only be imagined by those of us whose hands dampen only occasionally. Although there is no accurate incidence in the epidemiology literature, it appears that about half of the patients who have presented to us with this condition have at least one first degree relative similarly affected. Social stigma, lack of understanding on the part of medical providers as to the cause and nature of the problem, and lack of effective therapy keep most of these patients from seeking medical care. We will need a larger social sampling to accurately measure both the number of patients per 100,000 population who have the condition and the exact nature of the genetic influence.

Gravimetric measurements of palmar sweating show that patients with hyperhidrosis easily exceed 12 to 30 times normal rates of eccrine secretion from the palmar surface of the hands and fingers as well as the distal dorsal aspects of the fingers and sides of the hand and digits. Diagnostic rates arbitrarily defined in some patients exceed 50 mg of sweat per minute in the axillae and 30 mg of sweat per minute on the palms.¹⁻⁶

Whereas many patients sweat on a more or less continuous basis, even when asleep, many, if not most of the patients, report that they suffer from sudden, inexplicable increases in palmar sweating. These sweating attacks can be brought on by emotional stressors such as public speaking, meeting new social contacts at work or at leisure, high ambient temperature, and ingestion of stimulants like coffee. But some patients report that relative calmness without situational stress can even cause their hands to drip with sweat.

Many patients have covered this affliction by resorting to elaborate behavior rituals, such as repetitively wiping their palms on clothes, carrying towels and handkerchiefs at all times, and avoiding the dreaded handshaking at all costs. Traditional therapies, such as topical aluminum chloride salts in antiperspirants, anticholinergic drugs, and glutaraldehyde tinctures, are irritating, rife with side effects, and generally impractical for patients with this condition.^{2,7,8} Direct excision of the affected skin has been proposed for treating axillary sweating^{9,10} but cannot be performed on the palms. Liposuction curettage has been advocated for axillary hyperhidrosis,¹¹⁻¹⁶ but also is of no value in palmar sweating.

Standard surgical approach for palmar sweating has been focused on neurosurgical approaches with elective thoracic sympathectomies at the T2-T3 level, performed with endoscopic approaches and minimal incisions have been popular for some time.^{10,17-23}

The procedure carries risk of some significant postoperative complications, including Horner's syndrome, pneumothorax, and partial or incomplete response. Worse, significant portions of patients treated by sympathectomy develop some degree of compensatory hyperhidrosis.²⁴⁻²⁶ This condition affects the skin from the areolas caudally. The patients, although dry over the entire hand, arm, shoulder, neck and head, will paroxysmally sweat profusely from the midchest down. This is a

From the Department of Dermatology, University of California, San Francisco, CA.

The author is a retained consultant with both Allergan, Inc, Irvine, CA, manufacturer of BOTOX (purified botulinum neurotoxin A complex), and Elan Pharmaceuticals, South San Francisco, CA, manufacturer of MYOBLOC (purified botulinum neurotoxin B). Glogau's research presented in this article was partially sponsored by Allergan, Inc.

Address reprint requests to Richard G. Glogau, MD, Clinical Professor of Dermatology, University of California, San Francisco, 350 Parnassus Ave, Suite 400, San Francisco, CA 94117-3685.

*Copyright © 2001 by W.B. Saunders Company
1085-5629/01/2002-0005\$35.00/0
doi:10.1053/sder.2001.25140*

highly distressing and irreversible condition and no known algorithm to predict its occurrence preoperatively has yet been described. When compensatory hyperhidrosis occurs, the result is that one intolerable sweating problem is traded for another.

BOTULINUM TOXIN USE FOR SWEATING

There has been considerable interest in using selective, focal chemodenervation with botulinum neurotoxin to control problems of localized but severe sweating.^{1,3,20,27-49} At present, there are 2 commercially available forms of the A serotype complex, BOTOX (Allergan, Inc, Irvine, CA) and Dysport (Speywood Pharmaceuticals, Inc, Maidenhead, Berkshire, UK). A third commercially approved product, a B serotype, was recently approved by the FDA for cervical dystonia and is marketed in the United States as Myobloc (Elan Pharmaceuticals, South San Francisco, CA) and in Europe as Neurobloc. The A serotypes have accumulated more clinical experience in treatment of hyperhidrosis. The B serotype has not accumulated a significant clinical experience. For the balance of this discussion, reference is made to BOTOX unless otherwise specifically indicated.

Unlike sympathectomy, the area treated with BOTOX is confined to the palms or axillae or the sole. The total body surface area treated is less than 3%. In contrast, the surgical section of the sympathetic chain at the T2-T3 level renders at least 20% of the body's surface anhidrotic. Thermoregulatory stress then creates the compensatory sweating that has not been reported with focal chemodenervation with BOTOX to date.

DOCUMENTATION OF THE PROBLEM

There are 2 methods used to document the magnitude and distribution of abnormal palmar sweating: gravimetric measurement and Minor's iodine starch test. Gravimetric testing uses filter paper that is held in contact with the palm for a fixed period of time and then weighed (Fig 1). This technique is useful largely as a research tool to document the magnitude of sweat reduction and identify the therapeutic dose range. Minor's starch-iodine test is performed by first wiping the skin with a colored iodine tincture, eg, an antibacterial iodine solution available in pharmacies. The iodine solution must be brown-orange in color. Decolorized iodine solution will not perform the colorimetric conversion properly. Several seconds

are given to allow the iodine solution to dry. A small fan is useful for this purpose. The palm is then lightly dusted with ordinary baking cornstarch powder, available in any food store. As the eccrine sweat exits the skin onto the palmar surface, a chemical reaction takes place between the iodine molecule and the starch present in the powder producing a colorimetric reaction as the powder turns deep purple in a matter of a couple of seconds.

The exact location of the active sweating can then be mapped and outlined with a marking pen before beginning injections.

Take care to perform the starch iodine test before applying any regional nerve blocks or prior to application of topical anesthetics like prilocaine or eutectic mixtures of lidocaine (EMLA; Astra Pharmaceuticals, Wayne, PA) in wide use today. The vasoconstrictive effect of the topical anesthetics and the hyperemic response in the skin seen after regional wrist blocks both interfere with the amount of sweating and can give misleading results in the Minor starch-iodine test.

We have found it useful to take a digital photograph of the starch-iodine test for the medical record and to give a picture to the patients. They can easily perform a starch-iodine test themselves in follow-up and ascertain the fractional response to therapy. The photographs also help the patients visualize the degree of the problem and their response to therapy after the BOTOX injections are performed. Patients are psychologically traumatized by hyperhidrosis, and most are exquisitely sensitive to any persisting sweat after treatment (Fig 2). They are often reassured by comparing the before and after starch test pictures. It reinforces their understanding of the effect of the drug and the therapy.

ANESTHESIA

Most patients will require regional nerve block anesthesia, wrist blocks, prior to undergoing palmar injection.³² A few stoic patients may opt for simple topical anesthesia such as ice, EMLA, ELA-MAX (Ferndale Laboratories, Ferndale, MI), but few can tolerate the discomfort of 60 to 70 needle sticks per palm without anesthesia. One percent to 2% lidocaine plain, without epinephrine, is placed by superficial, subcutaneous injections at the wrist to produce blocks of the median, ulnar, and radial nerves. Once the injections are placed, usually a half-hour wait ensues to allow for the diffusion of anesthetic into the nerves to produce

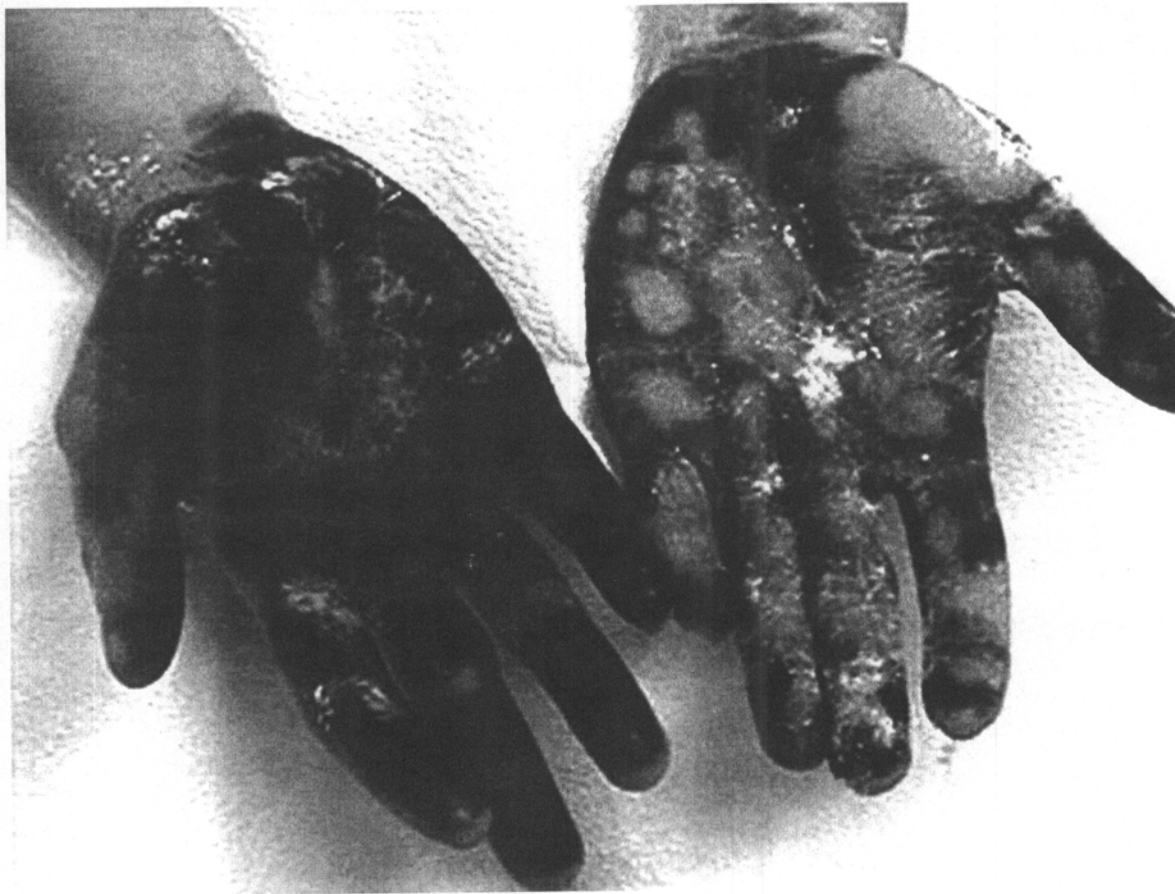

Fig 1. Minor starch-iodine test. Right hand untreated. Left hand 2 days after treatment with Botox. Note areas of diffusion with anhidrosis developing circumferentially around injection sites.

sufficient anesthesia. The disadvantage of using wrist blocks is that the patients reactive hyperemia that develops increases the tendency to bleed from each small injection site, which may increase loss of material from the injection site and decrease the relative effectiveness of each injection. Warning patients off aspirin prior to treatment is probably wise for the same reason.

INJECTION SYRINGES

The dosage of drug used and injection method has not been standardized. There are a variety of dosages reported in the literature.^{1,32,46,48,49} The author's technique is to use a dilution of 2.5 mL per 100 mouse units, dividing the whole bottle among 5 Ultrafine II 50 U insulin syringes (Becton-Dickinson, Franklin Lakes, NJ). Each syringe holds 0.5 mL and has the 30-gauge needle swaged directly into the chamber of the syringe, eliminating the dead space that occurs with a needle hub. This minimizes the

waste of expensive botulinum toxin. The syringes are filled by popping the metal cap and rubber stopper from the bottle and drawing up the BOTOX by aspirating with the needle inside the bottle. This is done to avoid needlessly dulling the 30-gauge needle by passing it through the rubber stopper.

INJECTION TECHNIQUE

Each syringe then holds 0.5 mL of solution (20 U); therefore, it is relatively easy to read the graduations on the syringe and place either 2 U (0.05 mL) or 4 U (0.1 mL) in each site. With practice, one can generate about 10 to 12 injections with each syringe.

The needle must enter the palmar skin at an oblique angle. Mechanical needle flanges have been advocated that provide a method for assisting the depth of the injection.^{32,50} But if the needle enters perpendicular to the skin surface, there is usually a significant amount of backflow of material that leaks out of the injection tract (Fig 3).

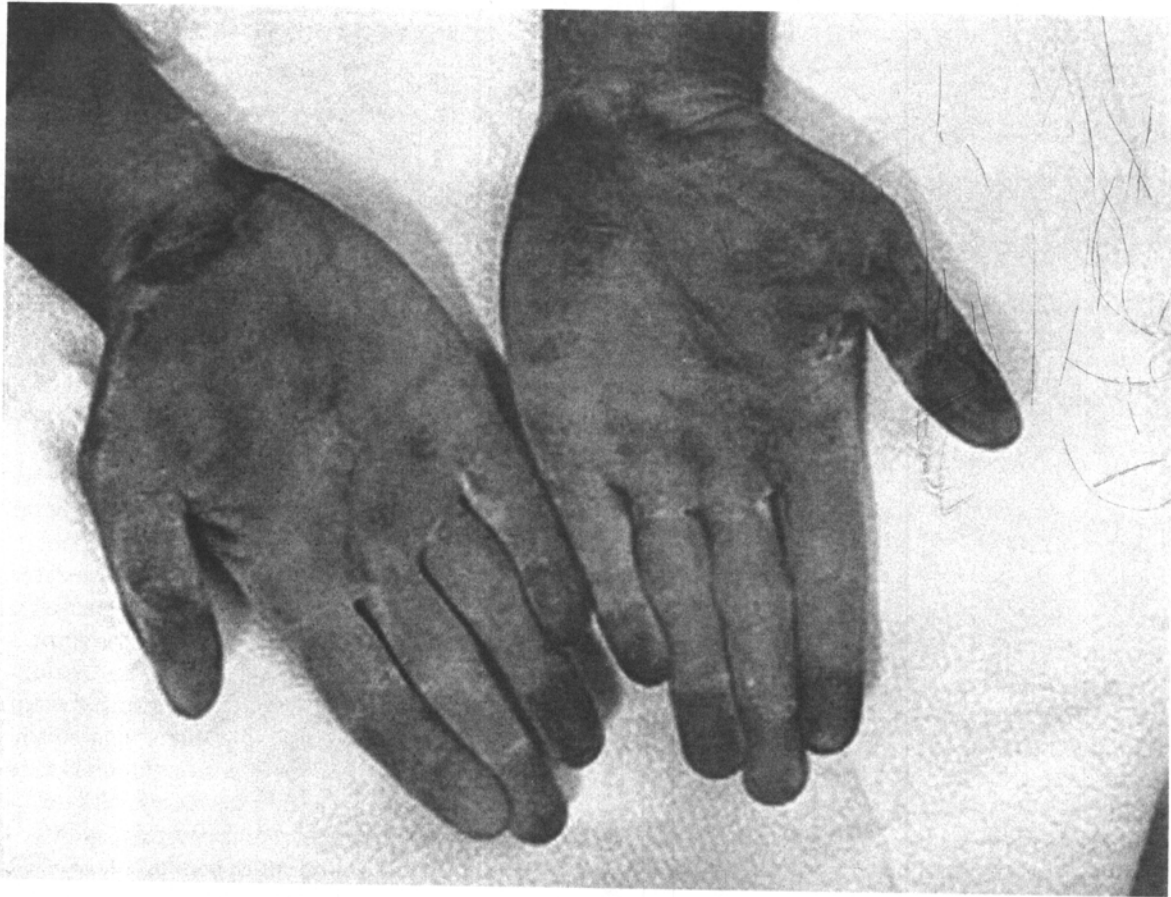


Fig 2. Minor starch-iodine test. Two weeks after treatment of both palms with Botox.

Because the volumes of BOTOX are typically small, this backflow significantly impacts the effectiveness of the injections. In axillary skin each injection is placed to produce a wheal. But the palmar skin is comparatively stiffer and usually a wheal cannot be raised under any circumstances.

However, it is desirable to produce a small zone of visible blanching, indicating that the material is in the deep dermis. Take care with each injection to remove the thumb from the plunger and allow a second or two for the pressure to normalize before withdrawing the needle from the skin or else the fluid will flow back out the injection tract directly.

INJECTION PATTERN AND DOSAGE

A representative sample of the dosage regimens, pattern of injection, and indications for the botulinum toxin are presented in Table 1.

In the author's technique, injections are placed approximately every 1.5 cm across the palmar surface. On the fingers the volar pad of each phalanx

receives its individual dose. The fingertips usually receive 2—one in midpad and another at the very tip as this is a problematic sweating area for people with hyperhidrosis. The dominant or writing hand also receives an extra row of injections along the ulnar side, midway between the palm and dorsal surface to provide maximum dryness for writing. Occasionally extra injections can be placed on the distal dorsal fingers or in the webs depending on the patient's complaints. The goal is to place the injections in a pattern so that diffusion will provide overlapping coverage for the entire palmar surface. One needs to minimize the number of injections that wind up subcutaneously as this increases the likelihood of diffusion of drug into the intrinsic muscles of the hand. The total amount of drug used per hand is, of course, dependent on the surface area of the hand. Patients with large shoe sizes have correspondingly larger hands and will require more drug. A man with a size 13 shoe (United States) will require up to 150

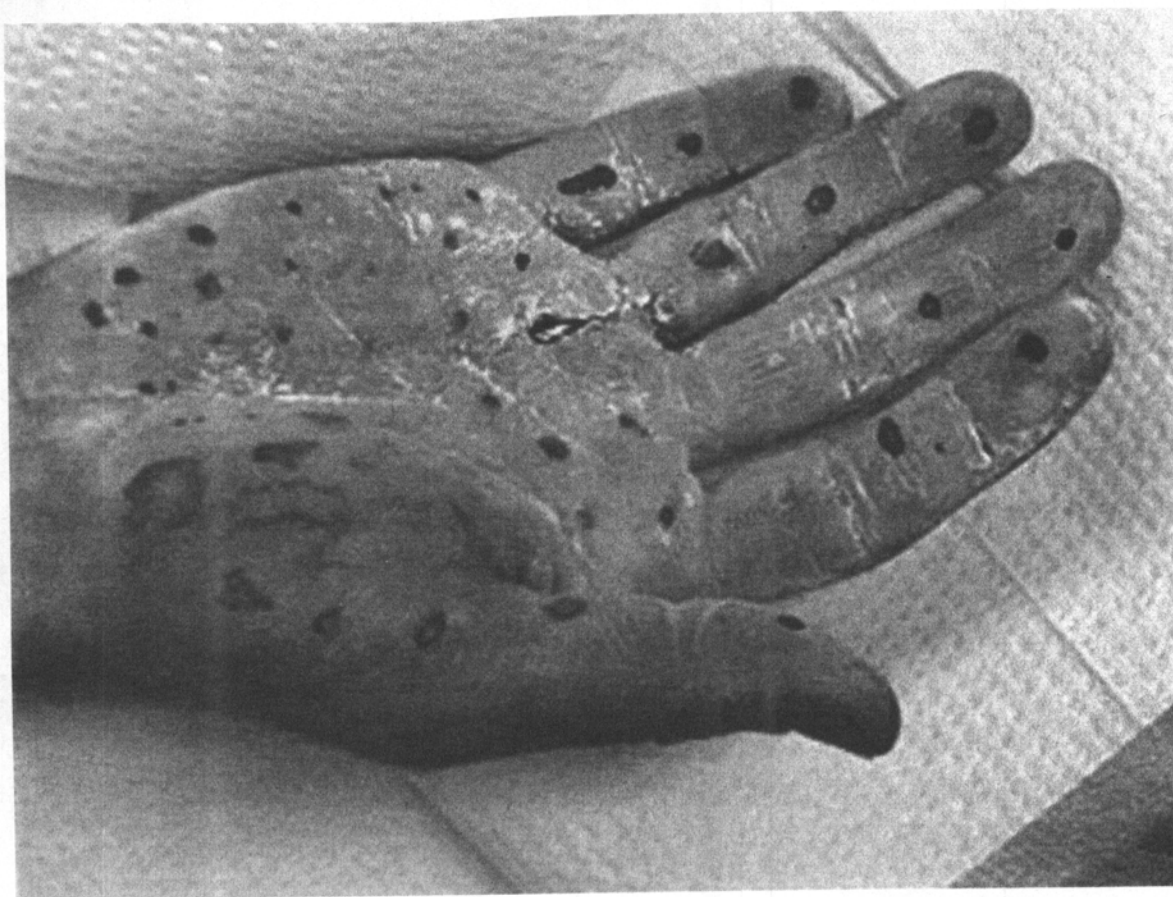


Fig 3. Minor starch-iodine test. Immediately after placing injections on the right palm. Note how minimal backflow was achieved in most, but not all, injection sites.

Table 1. Sample of Dosage Regimens and Patterns of Injections for Treatment of Hyperhidrotic Conditions With Botulinum Toxins

Author	Dilution	Dose (BOTOX Unless Otherwise Labeled)	Distance	Diagnosis
De Almeida, 2001 ³²	2.0	5	1.0 cm	Palmar
Heckmann, 2001 ³⁵	5.0	200 (Dysport)	10 fractions each	Axillary
Dulguerov, 2000 ⁵¹	2.0	5	1.0	Frey's
Karamfilov, 2000 ³⁷	1.0	200 (BOTOX)	Single dose	Axillary
Naver, 2000 ⁴³	?	2	4.0 cm ²	Axillary/palm
Solomon, 2000 ⁴⁸	2.0	2-4	1.0 cm	Palmar
Birch, 1999 ⁵²	4.0	7.5	6 cm ²	Frey's
Laccourreye, 1999 ⁵³		2.5	1.0 cm ²	Frey's
Schnider, 1999 ⁴⁷		33.3	2-3 cm	Axillary
Glogau, 1998 ³³	2.0	2	1.5 cm	Axillary
Heckmann, 1998 ⁵⁴		400 (Dysport)	1 cm	Axillary
Naumann, 1998 ¹		3	2 cm	Axillary, palm
Odderson, 1998 ⁴⁴		100 (BOTOX)		Axillary
Shelley, 1998 ⁴⁹		2	1 cm	Palmar
Schnider, 1997 ⁴⁶		20 U	6 sites	Palmar
Bushara, 1996 ²⁷		20-50	Single dose	Axillary
Cheshire, 1996 ³⁰		1 U	1.5 cm	Forearm
Drobik, 1995 ⁵⁵		0.5 U	1.0 cm	Frey's

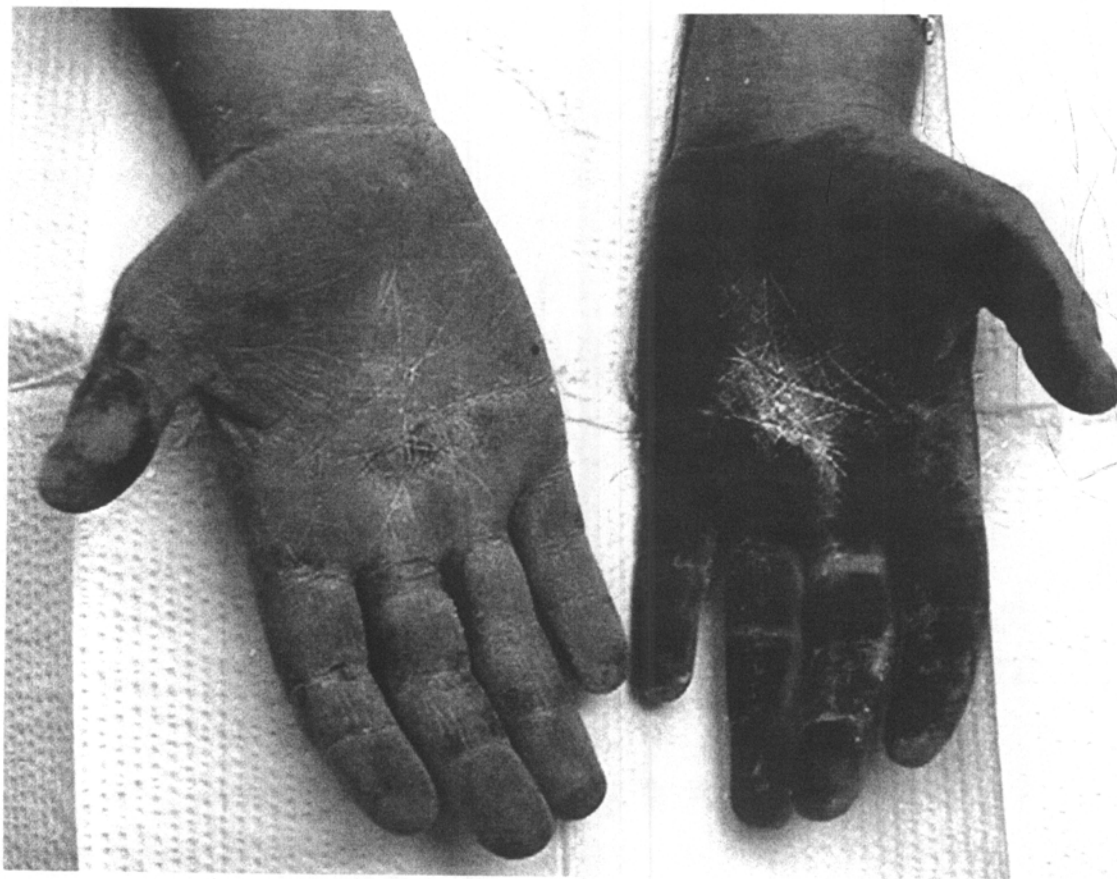

Fig 4. Minor starch-iodine test. Right hand treated 2 weeks previously. Left hand untreated.

U per palm, whereas a woman with a size 6 shoe (United States) may require as little as 75 U to cover the palm. The average dose in our patients was about 120 U per palm.

SCHEDULING TREATMENTS

Almost every patient who undergoes this treatment will develop a transient period of weakness and instability of the lumbrical muscles of the hand, which is predictably, spontaneously reversible.^{36,42,43,46,48,49,56} Tasks such as shoving a button through a tight button hold, holding heavy objects with chop sticks, or opening a stuck lock with a key will become problematic about 5 to 7 days after treatment and will remain so for 3 to 5 weeks. Patients can write, type, and eat, without difficulty, but opening up a tight jar lid will pose problems for a few weeks.

For this reason, if the patient can easily access the treating physician, it may be wise to stagger the treatments. Beginning with the right hand on

the first visit, we will often wait a couple of weeks and then treat the left hand with any needed touch up injections of the right hand on the second visit (Fig 4), and schedule a third visit to touch up the left hand. By doing so, one can stagger the time line of weakness to make it easier on the patient. However, multiple visits often are logistically impossible, and we have no objection to treating both palms simultaneously as long as the patient is aware of the implications. One successful strategy has been to offer to treat the hands separately the first time, but depending on the muscle weakness, let the patient choose to schedule future treatments together or staggered according to their own experience.

THERAPEUTIC RESPONSE

There is a definite range of responses to treatment, varying from about 3 to 12 months.^{36,42,43,46,48,49,56,57} The average in our hands is about 6 months. Interestingly, the effect does not seem as long as it is

with axillary hyperhidrosis. Speculative reasons for this may be the problem with backflow, the smaller diffusion distance in thicker palmar skin, the higher number of cholinergic nerve endings in the palmar skin, or a differential recovery rate between the nerves of the palm and those in the axillary skin. But on average, patients seem to require treatment about twice a year to maintain reasonable control of the palmar sweating. Patients are usually expecting complete anhidrosis as an endpoint, at least with their initial treatment. It may take several treatments before they recognize less than total response as successful. They are generally unfamiliar with normal palmar moisture, and at least initially, are intolerant of anything but a totally dry hand as a measure of success. With time and release from the mental anguish of unreliable palmar sweating, many do seem to change their therapeutic endpoint goals and are comfortable with control as opposed to total ablation of palmar sweating. Obviously, this changes the treatment intervals and dosages, but further work on patient acceptance needs to be undertaken.

To date, there have been no known reports of compensatory hyperhidrosis from the focal use of botulinum toxin in the palms or axillae. This is an

important theoretical and practical advantage of the botulinum toxins in the management of hyperhidrosis. The downside, of course, relates to the fact that the botulinum effect is neither permanent nor inexpensive. Properly informed patients may elect to pursue the surgical alternative, however, and referral should be made to neurosurgical or thoracic surgical practices with expertise in this method.

FUTURE DIRECTIONS

Further work will need to be done to optimize the dilution and units per square centimeter. Introduction of a botulinum toxin of the B serotype (Myobloc, Neurobloc, Elan Pharmaceuticals, Dublin, Ireland) may present an alternative molecule to the A serotypes currently in use. No data exist on the behavior of this molecule in the hyperhidrosis model at present. Work on injection delivery devices has stimulated some investigators and further enhancements to the delivery system may optimize the treatment for many patients. Further investigation of the genetic pattern of the disorder may give further clues to possible therapies. Until then the patients can benefit from life-altering therapy with this amazing molecule.

REFERENCES

1. Naumann M, Hofmann U, Bergmann I, et al: Focal hyperhidrosis: Effective treatment with intracutaneous botulinum toxin [see comments]. *Arch Dermatol* 134:301-304, 1998
2. Reinauer S, Neusser A, Schauf G, et al: Iontophoresis with alternating current and direct current offset (AC/DC iontophoresis): A new approach for the treatment of hyperhidrosis. *Br J Dermatol* 129:166-169, 1993
3. Heckmann M, Breit S, Ceballos-Baumann A, et al: Side-controlled intradermal injection of botulinum toxin A in recalcitrant axillary hyperhidrosis. *J Am Acad Dermatol* 41:987-990, 1999
4. Sato K, Kang W, Saga K, et al: Biology of sweat glands and their disorders. II. *J Am Acad Dermatol* 20:713-726, 1989
5. Sato K, Kang WH, Saga K, et al: Biology of sweat glands and their disorders. II. *J Am Acad Dermatol* 20:713-726, 1989
6. Sato K, Ohtsuyama M, Samman G: Eccrine sweat gland disorders. *J Am Acad Dermatol* 24:1010-1014, 1991
7. Shelley WB, Hurley HJ: Axillary hyperhidrosis. *JAMA* 233:1257, 1995 (letter)
8. Shelley WB, Hurley HJ, Jr: Studies on topical antiperspirant control of axillary hyperhidrosis. *Acta Derm Venereol* 55:241-260, 1975
9. Bisbal J, del CC, Casalots J: Surgical treatment of axillary hyperhidrosis. *Ann Plast Surg* 18:429-436, 1987
10. Cilliers PH: Surgical management of patients with hyperhidrosis. *S Afr Med J* 72:538-539, 1987
11. Christ JE: The application of suction-assisted lipectomy for the problem of axillary hyperhidrosis. *Surg Gynecol Obstet* 169:457, 1989
12. Coleman WD: Noncosmetic applications of liposuction. *J Dermatol Surg Oncol* 14:1085-1090, 1988
13. Lillis PJ, Coleman WD: Liposuction for treatment of axillary hyperhidrosis. *Dermatol Clin* 8:479-482, 1990
14. Shenaq SM, Spira M, Christ J: Treatment of bilateral axillary hyperhidrosis by suction-assisted lipolysis technique [published erratum appears in *Ann Plast Surg* 1990 Mar;24(3):212]. *Ann Plast Surg* 19:548-551, 1987
15. Swinehart J: Treatment of axillary hyperhidrosis: Combination of the starch-iodine test with the tumescent liposuction technique. *Dermatol Surg* 26:392-396, 2000
16. Tofield JJ: Treatment of bilateral axillary hyperhidrosis by suction-assisted lipolysis technique. *Ann Plast Surg* 21:99, 1988 (letter)
17. Chiou TS, Chen SC: Intermediate-term results of endoscopic transaxillary T2 sympathectomy for primary palmar hyperhidrosis [see comments]. *Br J Surg* 86:45-47, 1999
18. Drott C, Gothberg G, Claes G: Endoscopic transthoracic sympathectomy: An efficient and safe method for the treatment of hyperhidrosis. *J Am Acad Dermatol* 33:78-81, 1995
19. Goh PM, Cheah WK, De Costa M, et al: Needlescopic

- thoracic sympathectomy: Treatment for palmar hyperhidrosis. *Ann Thorac Surg* 70:240-242, 2000
20. Hashmonai M, Kopelman D, Assalia A: The treatment of primary palmar hyperhidrosis: A review. *Surg Today* 30:211-218, 2000
 21. Hsia JY, Chen CY, Hsu CP, et al: Outpatient thoracoscopic limited sympathectomy for hyperhidrosis palmaris. *Ann Thorac Surg* 67:258-259, 1999
 22. Lee KH, Hwang PY: Video endoscopic sympathectomy for palmar hyperhidrosis. *J Neurosurg* 84:484-486, 1996
 23. Yamamoto H, Kanehira A, Kawamura M, et al: Needle-surgical surgery for palmar hyperhidrosis. *J Thorac Cardiovasc Surg* 120:276-279, 2000
 24. Adar R: Compensatory hyperhidrosis after thoracic sympathectomy [see comments]. *Lancet* 351:231-232, 1998
 25. Collin J: Compensatory hyperhidrosis after thoracic sympathectomy [comment]. *Lancet* 351:1136, 1998 (letter)
 26. Shuster S: Compensatory hyperhidrosis after thoracic sympathectomy [comment]. *Lancet* 351:1136, 1998 (letter)
 27. Bushara K, Park D, Jones J, Schutta H: Botulinum toxin—A possible new treatment for axillary hyperhidrosis. *Clin Exp Dermatol* 21:276-278, 1996
 28. Bushara KO, Jones JC: Botulinum toxin and sweating. *Mov Disord* 10:391, 1995
 29. Bushara KO, Park DM: Botulinum toxin and sweating. *J Neurol Neurosurg Psychiatry* 57:1437-1438, 1994 (letter)
 30. Cheshire W: Subcutaneous botulinum toxin type A inhibits regional sweating: An individual observation. *Clin Auton Res* 6:123-124, 1996
 31. Collin J, Whatling P: Treating hyperhidrosis. Surgery and botulinum toxin are treatments of choice in severe cases [editorial]. *BMJ* 320:1221-1222, 2000
 32. de Almeida A, Kadung B, de Oliveira E: Improving botulinum toxin therapy for palmar hyperhidrosis: Wrist block and technical considerations. *Dermatol Surg* 27:34-36, 2001
 33. Glogau R: Botulinum A neurotoxin for axillary hyperhidrosis. No sweat Botox. *Dermatol Surg* 24:817-819, 1998
 34. Goldman A: Treatment of axillary and palmar hyperhidrosis with botulinum toxin. *Aesthetic Plast Surg* 24:280-282, 2000
 35. Heckmann M, Ceballos-Baumann A, Plewig G: Botulinum toxin A for axillary hyperhidrosis (excessive sweating). *N Engl J Med* 344:488-493, 2001
 36. Holmes S, Mann C: Botulinum toxin in the treatment of palmar hyperhidrosis [letter; comment]. *J Am Acad Dermatol* 39:1040-1041, 1998
 37. Karamfilov T, Konrad H, Karte K, et al: Lower relapse rate of botulinum toxin A therapy for axillary hyperhidrosis by dose increase [see comments]. *Arch Dermatol* 136:487-490, 2000
 38. Jansen T: [Botulinum toxin A for treatment of localized hyperhidrosis]. *MMW Fortschr Med* 141:46, 1999
 39. Kreyden O, Burg G: Toxin treatment of sweat pearls. A review of the treatment of hyperhidrosis with a special view of a new therapy option using botulinum toxin A. [In Process Citation]. *Schweiz Med Wochenschr* 130:1084-1090, 2000
 40. Leung A: Botulinum toxin therapy for hyperhidrosis. *Int J Dermatol* 39:160, 2000 (letter)
 41. Markey A: Botulinum A exotoxin in cosmetic dermatology. *Clin Exp Dermatol* 25:173-175, 2000
 42. Naumann M, Bergmann I, Hofmann U, et al: Botulinum toxin for focal hyperhidrosis: Technical considerations and improvements in application [letter]. *Br J Dermatol* 139:1123-1124, 1998
 43. Naver H, Swartling C, Aquilonius S: Palmar and axillary hyperhidrosis treated with botulinum toxin: One-year clinical follow-up. *Eur J Neurol* 7:55-62, 2000
 44. Odderson I: Axillary hyperhidrosis: Treatment with botulinum toxin A. *Arch Phys Med Rehabil* 79:350-352, 1998
 45. Odderson I: Hyperhidrosis treated by botulinum A exotoxin. *Dermatol Surg* 24:1237-1241, 1998
 46. Schnider P, Binder M, Auff E, et al: Double-blind trial of botulinum A toxin for the treatment of focal hyperhidrosis of the palms [see comments]. *Br J Dermatol* 136:548-552, 1997
 47. Schnider P, Binder M, Kittler H, et al: A randomized, double-blind, placebo-controlled trial of botulinum A toxin for severe axillary hyperhidrosis. *Br J Dermatol* 140:677-680, 1999
 48. Solomon B, Hayman R: Botulinum toxin type A therapy for palmar and digital hyperhidrosis. *J Am Acad Dermatol* 42:1026-1029, 2000
 49. Shelley W, Talanin N, Shelley E: Botulinum toxin therapy for palmar hyperhidrosis [see comments]. *J Am Acad Dermatol* 38:227-229, 1998
 50. Zaiac M, Weiss E, Elgart G: Botulinum toxin therapy for palmar hyperhidrosis with ADG needle. *Dermatol Surg* 26:230, 2000
 51. Dulguerov P, Quinodoz D, Cosendai G, et al: Frey syndrome treatment with botulinum toxin. *Otolaryngol Head Neck Surg* 122:821-827, 2000
 52. Birch J, Varma S, Narula A: Botulinum toxoid in the management of gustatory sweating (Frey's syndrome) after superficial parotidectomy. *Br J Plast Surg* 52:230-231, 1999
 53. Laccourreye O, Muscatello L, Gutierrez-Fonseca R, et al: Severe Frey syndrome after parotidectomy: Treatment with botulinum neurotoxin type A. *Ann Otolaryngol Chir Cervicofac* 116:137-142, 1999
 54. Heckmann M, Breit S, Ceballos-Baumann A, et al: [Axillary hyperhidrosis: Successful treatment with botulinum toxin A (see comments)]. *Hautarzt* 49:101-103, 1998
 55. Drobik C, Laskawi R: Frey's syndrome: Treatment with botulinum toxin. *Acta Otolaryngol* 115:459-461, 1995
 56. Naumann M, Flachenecker P, Brocker E, et al: Botulinum toxin for palmar hyperhidrosis [see comments]. *Lancet* 349:252, 1997 (letter)
 57. Heckmann M: Evaluation of therapeutic success of hyperhidrosis therapy. *Arch Dermatol* 137:94, 2001