

Tap Water Iontophoresis

Mark D. Anliker^a, Oliver P. Kreyden^b

^a Dermatology Unit, Department of Medicine, Kanton Hospital of Aarau, and

^b Department of Dermatology, University Hospital of Zurich, Switzerland

There are many effective therapeutic options in the treatment of hyperhidrosis. Besides the approach of treating the psychovegetative disorder with autogenic training or acupuncture, there are treatment modalities that seal the lumen of terminal sweat ducts using aluminium chlorohydroxide (see chapter 'Topical pharmacological treatment') or iontophoresis. In general, the treatment of a focal essential hyperhidrosis should be approached in a stepwise manner (fig. 1).

Tap water iontophoresis (TWI) is the first line of treatment in palmoplantar hyperhidrosis [1, 2]. Without using invasive procedures, it is safe, well tolerated and has been shown to be very efficient. It is widely used in practical dermatology and has constantly been optimized since its introduction 30 years ago. The efficacy is undoubted; however, the mechanisms that lead to anhidrosis have still not been clarified completely. Since electricity became available, scientists have been fascinated by the idea of using it for therapeutic reasons on the human body; however, most approaches have been abandoned again. Today iontophoresis is making a comeback, and the possibility of enhancing the delivery of substances to certain sites of the body by means of electricity is reviving science in this field [3–5].

History

Therapeutic administration of electricity has been known for over two centuries; first reports from Kratzenstein (1723–1795) and Galvani (1737–1798) were published in the mid-18th century [6]. Already in 1740, Pivati used iontophoresis in the treatment of arthritis [7]. The mechanisms of iontophoresis are based on the principles of electricity: elements with the same charge repel and

Therapy of hyperhidrosis

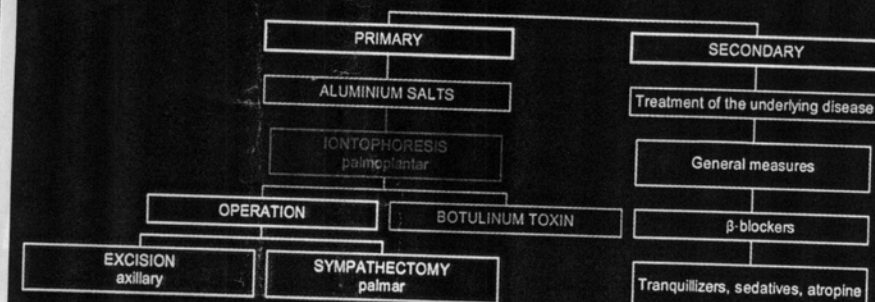


Fig. 1. Flow chart of treatment options for primary or focal and secondary or generalized hyperhidrosis. Some therapy modalities are more suitable for axillary hyperhidrosis (i.e. aluminium salts), others are more useful in the treatment of palmoplantar hyperhidrosis (i.e. iontophoresis). Systemic treatment is preferable in the treatment of generalized hyperhidrosis.

contrarily charged ones attract each other. In this way, by the use of an external source of energy (electrode), the penetration of charged molecules (which otherwise would hardly cross the epidermis) is facilitated. To deliver a charged substance across the epidermis, it must be placed close to the electrode with the same polarity, where it will be repelled in the direction of the electrode with the opposite charge. This electrode is placed on another part of the body. In anodal iontophoresis, positively charged substances are applied onto the skin under the anode at the site intended to treat, while the cathode, the 'receiving' electrode, is placed at a neutral site [3, 5, 7].

It is assumed that the main transport (passage) occurs via the pores of the sweat glands besides a small proportion of paracellular and follicular trafficking [7-9].

The transport is also dependant on physical, biological and chemical factors such as concentration, size, hydrophilicity, lipophilicity and polarity of the molecules, current or skin factors [5, 7-10].

The systemic effect of this technique was demonstrated by Munch in 1879, when he was able to kill a rabbit with strychnine delivered by transepidermal iontophoresis. However, it was Leduc [3, 7, 11] who was accredited for this finding in the early 20th century, who undertook the same experiment on two rabbits which died after transepidermal iontophoresis of strychnine and cyanide.

These experiments showed convincingly that iontophoresis is an efficient method to deliver pharmaceuticals into and across the skin [11]. As Köstner mentioned: 'Using the skin organ as a primary target, dermatology devoted itself to iontophoresis early on.'

A wave of enthusiasm for the use of iontophoresis was stimulated and led to its application in different fields of medicine, pharmacology and biology [6, 7, 12, 13]; for instance the quantitative pilocarpine iontophoresis test, in which the quantity of excreted sweat is measured in the diagnosis of mucoviscidosis, a test still widely used in pediatrics. Another example is the lidocaine iontophoresis for anesthesia of the eyelid, ear canal or in surgery of the jaw region, where classic anesthesia is difficult. Other applications of iontophoresis were conducted with topical antirheumatic agents; these, however, lost their advantage with the introduction of improved sterility in subcutaneous and intramuscular injections [7].

One of the remaining advantages of transepidermal iontophoresis is to avoid the first-pass effect of the liver. This form of drug delivery allows us to minimize the loss of potent and costly molecules such as peptides, antigens and hormones without invasive measures. At the same time, the potential risk of infection is avoided [7]. Molecules that would be too large, complex, bipolar or hydrophobic for passive diffusion across the epidermis can penetrate on behalf of an artificial current (anodal or cathodal iontophoresis).

In dermatology, too, many possible applications of iontophoresis were practiced and discussed [6, 11–13], whereas today palmoplantar hyperhidrosis remains the only clear indication for iontophoresis (TWI). For instance, the use of iontophoresis with meladinine is controversial in the treatment of vitiligo for repigmentation [11, 12] or the therapy of lymphedema and scleredema with the iontophoretic application of hyaluronidase, which should result in the reduction of the diameter of the treated extremity. Further reports mention the iontophoretic delivery of sodium disulfide locally in constitutional hypertrichosis and steroids in induratio penis plastica with taking advantage of the antithrombotic capacity of the galvanic current [6].

According to Sloan and Soltani [11], 'the most successful and popular application of iontophoresis for dermatologic conditions is the treatment of hyperhidrosis'.

Tap Water Iontophoresis

In 1936, Ichikasi noticed that the iontophoretic application of pharmacological substances reduced sweating in those areas [11]. However, it was Takata in 1942 and Shelley in the same year (without knowledge of Takata's work)

Table 1. Side effects in TWI are rare and modest [15-17, 22]

Sensations (dysesthesias and burning)
Erythema, urticae, formation of vesicles along the water surface
Electric stings by abrupt change in voltage
Punctate electric burns in unnoticed skin defects

who achieved anhidrosis by the use of iontophoresis with mere tap water [6, 8, 14]. But it was only in 1968 when Levit introduced TWI in practical dermatology for the treatment of palmoplantar hyperhidrosis [14, 15]. Since then, several authors have investigated the efficacy and methods of TWI, concluding that the reduction of hyperhidrosis was remarkable, also in double-blind placebo-controlled settings.

Until now it has not quite been understood, which mechanism leads to the inhibition of palmoplantar hyperhidrosis in TWI. Several hypotheses were established, including the obstruction of the distal sweat gland by a keratin plug in experiments by Shelley. In microscopic and electron-microscopic studies however [16, 17], these changes could not be verified. Instead, anhidrosis would be achieved by a transient functional impairment, either by blocking the neuroglandular transmission, by inhibition of the secretory mechanism on the cellular level or by elevating the necessary stimulus threshold of the eccrine glands [15, 17].

However, Wang et al. [18] demonstrated that the composition of neurotransmitters does not change in the secretory part of the gland or dermal microcirculation after iontophoretic treatment.

Sato et al. [8] suggested, after observing an accumulation of H^+ ions in TWI in the ductal and secretory part of the sweat gland, that these structures undergo destructive changes due to an environment of low pH, resulting in hypo- or anhidrosis. These changes could include chronic ductal obstruction causing an increased ductal pressure and leakiness of the intracellular junction. This would also explain the greater efficacy of anodal iontophoresis compared to the cathodal side. Indeed, according to their investigations, the pH medium in the anodal pan reaches approximately 3, whereas in the cathodal pan a pH medium up to 10 could be measured.

Until recently, TWI has been performed using direct current (DC) employing an amperage of 8-25 mA at a voltage of 20-40 V. Using alternating current with direct current offset (AC/DC), the same efficacy was achieved with a lower current (8-12 mA) and a fixed voltage of 16 V. In this mode, side effects (table 1), which are rare anyway (irritation of the skin, electric stings), are minimized [19-21] (table 1). Using DC, the skin cannot depolarize, whereas in AC with DC offset, using the right frequency (4.3-10 kHz) and waveform (0-16 V sawtooth waveform), it can.

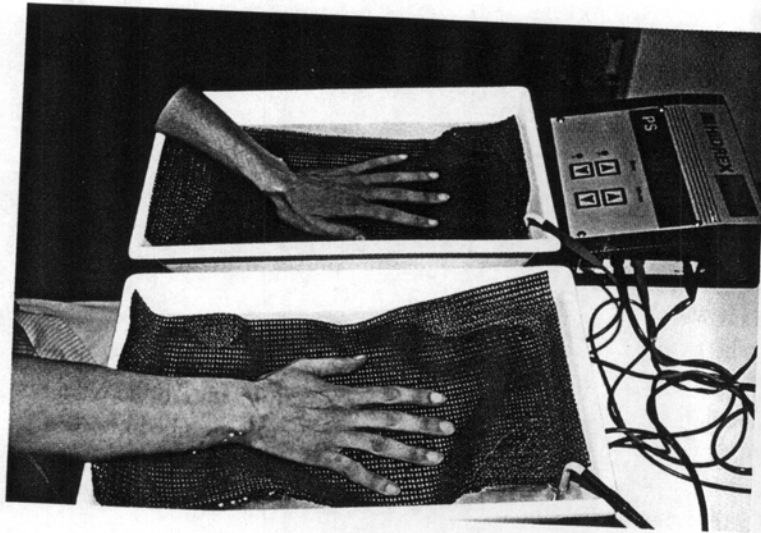


Fig. 2. TWI. The anodal and cathodal pans are filled just enough to cover both hands.

Treatment Scheme with Tap Water Iontophoresis

An ideal, optimized treatment scheme was suggested by Schauf et al. [22]. In the initial phase, TWI (fig. 2) is performed 3–5 times a week for 10 min, keeping one side (extremity) in the anodal pan for every treatment session until normohidrosis is reached on that side (for current and voltage used in DC and AC/DC devices, see above). Thereafter sides are switched until normohidrosis is achieved on both sides. The maintenance therapy is individual and is usually necessary 1–3 times a week for 10 min, switching the anode and the cathode after every treatment. In our experience [unpubl. data] and on the basis of other reports, the polarity should be changed after half the time of each therapy to achieve the same results on both palms or soles. The treatment medium used is normal nondeionized tap water [22]. The least side effects and good efficacy result from AC/DC with a frequency of 10 kHz [20]. TWI devices are available using AC/DC, batteries or a rechargeable power supply [7, 23].

Indications for the Treatment with Tap Water Iontophoresis

TWI is generally used in the treatment of palmar or palmoplantar hyperhidrosis that does not respond to local treatment. It is well accepted and well

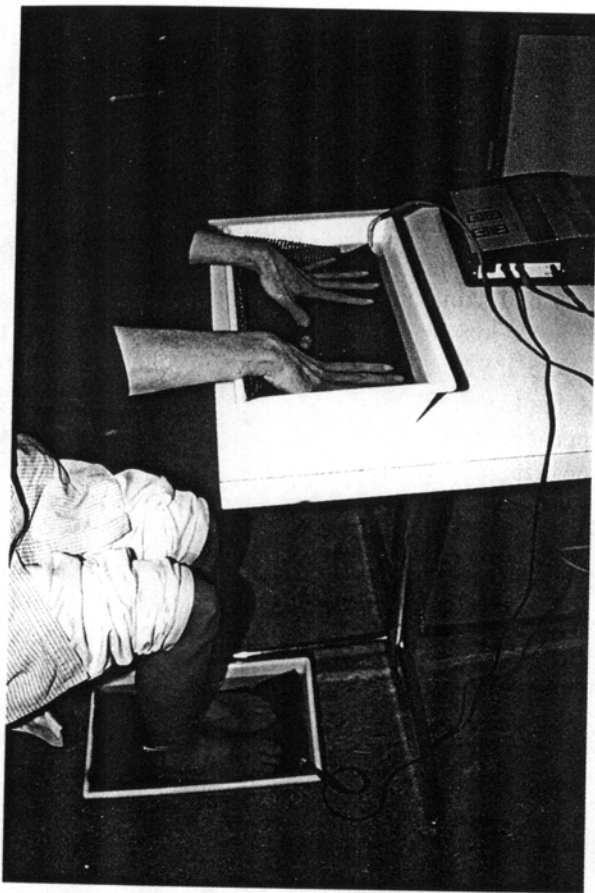

Fig. 3. In the treatment of palmoplantar hyperhidrosis, TWI is conducted simultaneously, with hands and feet in separate pans.

documented, is noninvasive and is usually granted cover by the health insurance (home treatment device). In palmoplantar hyperhidrosis, TWI is conducted simultaneously, holding hands and feet into separate pans (fig. 3), applying the same treatment scheme as for hands or feet alone.

For axillary hyperhidrosis, additional electric sponges can be used after protecting the skin with a thin layer of vaseline. It is, however, less effective due to disturbing side effects [24]. Nonresponders can be treated by a local 20% aluminium hexahydrate gel overnight [25], by intradermal application of botulinum toxin [26, 27] or by surgical intervention (elliptical excision, liposuction, curettage) [28–30].

In certain conditions associated with hyperhidrosis of the extremities, TWI can also be helpful treating the underlying disease, such as Sudek's disease [31], pitted keratolysis, gram-negative infections of the feet, mycotic infections and warts associated with hyperhidrosis [own observation]. In some cases, TWI is the only reasonable option in the long term to avoid relapsing infections of the feet prone to hyperhidrosis.

Successful TWI of dyshidrotic hand eczema with hyperhidrosis has been reported [32]. Our own experiences and investigations however show that individuals with hand eczema and skin subject to irritation, documented by an increased transepidermal water loss or high Erlanger score for atopic risk factors [33, 34], do not tolerate TWI well [35]. A sufficient voltage for the treatment cannot be reached due to stinging, burning and additional formation of vesicles, which can also appear in responders in the initial 2 weeks of treatment. However, after successful local treatment of dermatitis and a sufficient skin barrier, treatment by TWI may be tried in patients with dyshidrotic hand eczema and concomitant palmar hyperhidrosis.

Although in most cases TWI is effective, there are nonresponders who do not reach sufficient anhidrosis. For these patients alternative treatments should be provided. For others, treatment with TWI is successful, but the willingness and self-discipline to conduct TWI 2–3 times a week may be hampered. In a collective of 15 patients undergoing TWI with a home treatment device, we conducted an inquiry by mail and phone on the efficacy and satisfaction with TWI. 2/15 had moved to other countries, 11/13 (85%) of the others were still using the equipment after a median duration of 14 months 1–5 times a week (median 2.2 times a week). For the 2 who had not continued the therapy, TWI had not been effective enough after all.

Basically, two alternatives for the treatment of hyperhidrosis of the limbs can be suggested in case of nonresponse to or dissatisfaction with TWI: the local infiltration with botulinum toxin [36] and endoscopic trans-thoracic sympathectomy [37], which are both discussed in other chapters of this book.

References

- 1 Lamming C, Petzoldt D: Palmoplantare Hyperhidrosis. *DMW* 1993;118:1910.
- 2 Hölzle E, Pauli M, Braun-Falco O: Leitungswasser-Iontophorese zur Behandlung von Hyperhidrosis manuum et pedum. *Hautarzt* 1984;35:142–147.
- 3 Singh J, Maibach HI: Topical iontophoretic drug delivery in vivo: Historical development, devices and future perspectives. *Dermatology* 1993;187:235–238.
- 4 Singh P, Anliker MD, Maibach HI: Facilitated Drug Delivery during Transdermal Iontophoresis. *Curr Probl Dermatol*. Basel, Karger, 1995, vol 22, pp 184–188.

- 5 Singh P, Anliker MD, Smith GA, Zavortink D, Maibach HI: Transdermal iontophoresis and solute penetration across excised human skin. *J Pharmacol Sci* 1995;84:1342-1346.
- 6 Köstler E: Die Bedeutung der Iontophorese in der Dermatologie. *Dermatol Monatsschr* 1977;163:689-699.
- 7 Singh P, Maibach HI: Iontophoresis in drug delivery: Basic principles and applications. *Crit Rev Ther Drug Carrier Syst* 1994;11:161-213.
- 8 Sato K, Timm DE, Sato F, et al: Generation and transit pathway of H⁺ is critical for inhibition of palmar sweating by iontophoresis in water. *J Appl Physiol* 1993;75:2258-2264.
- 9 Papa CM, Kligman AM: Mechanisms of eccrine anhidrosis. II. The antiperspirant effect of aluminium salts. *J Invest Dermatol* 1967;42:139-145.
- 10 Singh P, Guy RH, Roberts MS, Maibach HI: What is the transport-limiting barrier in iontophoresis? *Int J Pharm* 1994;101:1-5.
- 11 Sloan JB, Soltani K: Iontophoresis in dermatology. *J Am Acad Dermatol* 1986;15:671-684.
- 12 Moawad MB: Treatment of vitiligo with 1% solution of the sodium salt of meladinine using the iontophoresis technique. *Dermatol Monatsschr* 1969;155:388-394.
- 13 Popkin RJ: The use of hyaluronidase by iontophoresis in the treatment of generalized scleroderma. *J Invest Dermatol* 1950, pp 97-102.
- 14 Shrivastava SN, Singh G: Tap water iontophoreses in palmo/plantar hyperhidrosis. *Br J Dermatol* 1977;96:189-195.
- 15 Raulin C, Rösing S, Petzoldt D: Heimbehandlung der Hyperhidrosis manuum et pedum durch Leitungswasser-Iontophorese. *Hautarzt* 1988;39:504-508.
- 16 Hill AC, Baker GF, Jansen GT: Mechanism of action of iontophoresis in the treatment of palmar hyperhidrosis. *Cutis* 1981;28:69-72.
- 17 Hölzle E, Alberti N: Long-term efficacy and side effects of tap water iontophoresis of palmo/plantar hyperhidrosis - the usefulness of home therapy. *Dermatologica* 1987;175:126-135.
- 18 Wang L, et al: No change in skin innervation in patients with palmar hyperhidrosis treated with tap-water iontophoresis. *Br J Dermatol* 1994;131:742-743.
- 19 Reinauer S, Neusser A, Schauf G, Hölzle E: Die gepulste Gleichstrom-Iontophorese als neue Behandlungsmöglichkeit der Hyperhidrosis. *Hautarzt* 1995;46:543-547.
- 20 Reinauer S, Neusser A, Schauf G, Hölzle E: Iontophoresis with alternating current and direct current offset (AC/DC iontophoresis): A new approach for the treatment of hyperhidrosis. *Br J Dermatol* 1993;129:166-169.
- 21 Hölzle E: Therapie der Hyperhidrosis. *Hautarzt* 1984;35:7-15.
- 22 Schauf G, Hubert M, Reinauer S, Hölzle E: Modifikation und Optimierung der Leitungswasser-Iontophorese. *Hautarzt* 1994;45:756-761.
- 23 Plewig G, Nachbar F, Blecher P, Hüttenrauch C: Hyperhidrosis und Iontophorese: Nicht jedes Gerät wirkt gleich. *Z Dermatol* 1995;181:43-44.
- 24 Elgart ML, Fuchs G: Tapwater iontophoresis in the treatment of hyperhidrosis. *Int J Dermatol* 1987;20:194-197.
- 25 Shelley WB, Hurley HJ: Studies on topical antiperspirant control of axillary hyperhidrosis. *Acta Derm Venereol (Stockh)* 1975;55:241-260.
- 26 Heckmann M, Breit S, Ceballos-Baumann A, Schaller M: Axillary hyperhidrosis: Successful treatment with botulinum toxin-A. *Hautarzt* 1998;49:101-103.
- 27 Kreyden OP, Böni R, Burg G: Type A botulinum toxin: A new method in treating focal hyperhidrosis. A summary of various possibilities in hyperhidrosis therapy with special emphasis to type A botulinum toxin injections. *Schweiz Rundsch Med Prax* 2000;89:909-915.
- 28 Hurley HJ, Shelley WB: Simple surgical approach to the management of axillary hyperhidrosis. *JAMA* 1963;186:109.
- 29 Lillis PJ, Coleman WP: Liposuction for treatment of axillary hyperhidrosis. *Dermatol Clin* 1990;8:479-482.
- 30 Hasche E, Hagedorn M, Sattler G: Treatment of axillary hyperhidrosis by liposuction with tumescent regional anaesthesia. *Hautarzt* 1997;48:817-819.
- 31 Reinauer S, Goerz G, Hölzle E, Heusgen F, Dinter W, Tarnow J, Ruzicka T: Distal edema and hyperhidrosis of the arm. Symptom of reflex sympathetic dystrophy (Sudeck's disease). *Hautarzt* 1994;45:696-701.