

# Chromophore Mapping of Hemoglobin for the Assessment of Axillary Irritation: Comparison of OTC and Prescription Antiperspirants

Lola Kelly Smalls, PhD, MBA, Laurie Elstun, MS, Amy Capretta, BS, Paula Hartwig, BS, Michael Thomas, MBA, David Swaile, PhD, P&G Beauty, Cincinnati, Ohio USA

## INTRODUCTION

Prescription (Rx) antiperspirant (AP) products are widely known to induce irritation (erythema, stinging, burning) due to the highly acidic nature of the AP active in vehicles that are not optimized to buffer the skin reactions. This axillary skin irritation limits patient compliance, thus impeding product efficacy. Previously, we shared data from two well-controlled clinical studies that established the prescription strength AP efficacy for an OTC AP compared to a Rx AP<sup>1</sup>. This prescription strength wetness protection OTC AP was formulated to be gentle to the skin by delivering skin-soothing benefits via petrolatum and dimethicone. In these clinical studies we demonstrate the utility of non-contact SIAScropy (Spectrophotometric Intracutaneous Analysis, NCS), an image analysis method that maps skin chromophores (hemoglobin, eumelanin, dermal collagen)<sup>2,3,4</sup>, to examine the regional distribution and concentration of hemoglobin in axillary skin treated with a mild OTC AP and an irritating prescription AP.

## OBJECTIVE

Evaluate the utility of non-contact SIAScropy for the assessment of axillary irritation via chromophore mapping of hemoglobin with comparison to expert clinical and subject perceived irritation in axillary skin treated with a mild prescription strength wetness protection OTC AP and an irritating prescription AP.


## METHODS

Two well-controlled, randomized and blinded paired comparison clinical studies were conducted to evaluate axillary irritation and AP efficacy of a Rx AP containing 6.25% Aluminum Chloride versus an OTC anhydrous, Aluminum Trichlorohydrate GLY AP. The study was conducted for 7-days in healthy females (n=19), with treatments applied 1X/day in the evening. The panels were evaluated for irritation at each visit. If a panelist had an irritation score of 2 or above (Scale: 0=None to 3=Extreme), product application was discontinued for subject safety and the highest irritation and image scores for that panelist were carried forward for the analysis. Study measurements: Daily high resolution image capture for subsequent non-contact SIAScropy evaluation, AP efficacy (Post-trt 6), daily expert irritation scoring, and daily subject self-reported symptoms. The data were assessed using mixed models or the marginal homogeneity test.

## RESULTS

Non-contact chromophore mapping of hemoglobin indicated that there was significantly ( $p<0.05$ ) more irritation for the Rx AP as compared to the OTC AP (Visits 3-7). Additionally, the hemoglobin data were consistent with significant findings ( $p<0.05$ ) for expert clinical visual irritation scores (Visits 3-7) and subject self-assessments ( $p<0.05$ , Visits 3-7). Subject perception data indicated that the irritation from the Rx AP most often felt like stinging and burning. For subject safety, treatment was discontinued at level 2 irritation (Scale:0-3): n=7 on Rx AP and n=0 on Anhydrous OTC AP.

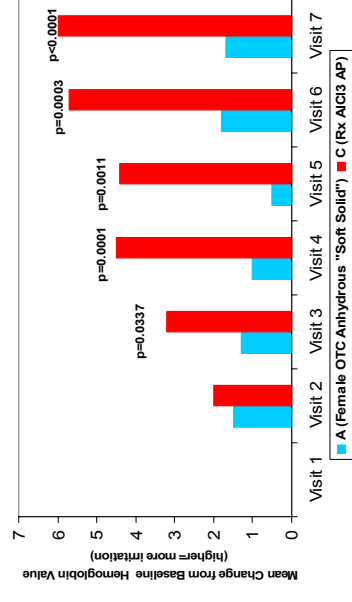
### Anhydrous "Soft Solid" OTC AP



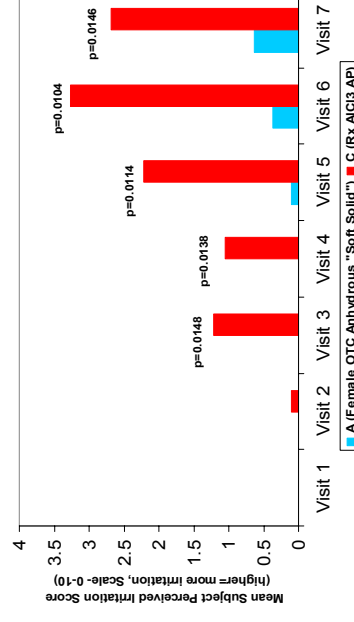
### Rx Aluminum Chloride AP

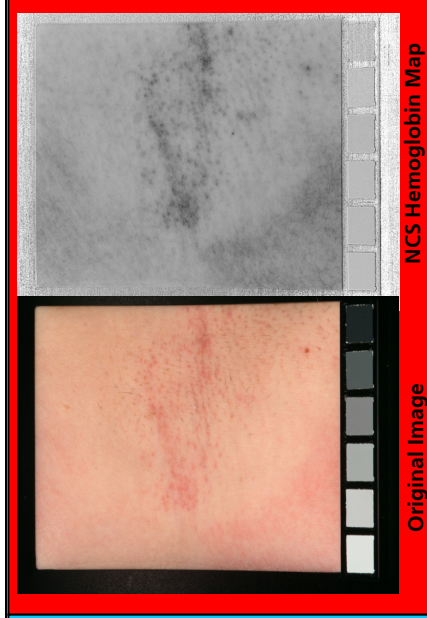

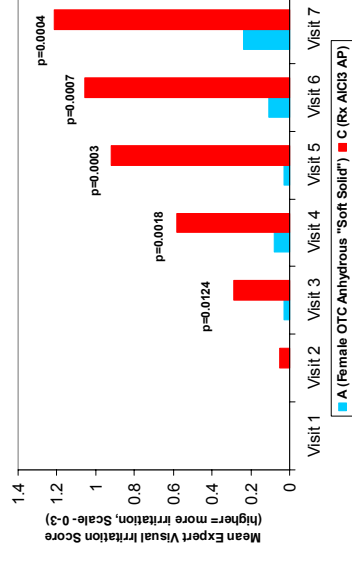
Image Analysis- Change from Baseline Hemoglobin Values



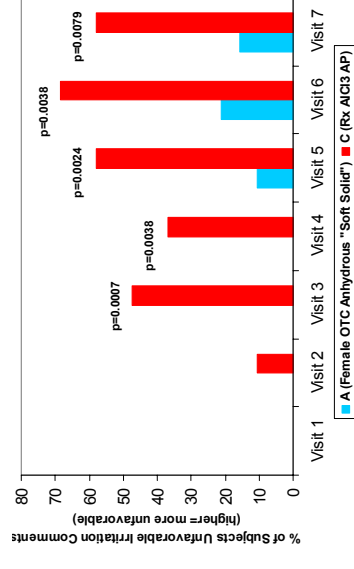
Subject Self Perceived Irritation Score by Visit



Expert Visual Irritation Assessment by Visit



Subject Self-Perceived Irritation Unfavorable Comments



## CONCLUSIONS

- Overall, these data demonstrate that non-contact chromophore mapping via SIAScropy is an effective tool for the assessment of axillary irritation and is consistent with expert clinical irritation assessments, and subject self-perceived data.
- Additionally, the milder "Soft Solid" OTC AP may increase subject compliance, leading to a more consistent treatment regimen as compared to the more irritating Rx Aluminum Chloride AP.

Currently, the image analysis method works well in shaved underarm skin. The method has not been optimized for unshaved skin. In clinical trials, expert irritation assessment is always recommended in conjunction with image analysis methods.

### Acknowledgements:

Image Analysis by Michael Marmor & Kukizo Miyamoto.

### References

- Thomas M, Kelly Smalls LR, Leazer TM, Finn E, Elstun LT, Hartwig P, Swaile D, Capretta A. Alternative Topical Treatment to an Aluminum Chloride Antiperspirant that Provides Prescription Strength Efficacy with Significantly Less Irritation. American Academy of Dermatology 65<sup>th</sup> Annual Meeting, 2007.
- Matts PJ, Frink B, Grammer K, Burquest M. Color homogeneity and visual perception of age, health, and attractiveness of female facial skin. *J Am Acad Dermatol* 2007; 57:977-84.
- Matts PJ, Carey J, Cotton SD. Chromophore mapping: a new technique to characterize aging human skin, *in vivo*. American Academy of Dermatology 63<sup>rd</sup> Annual Conference, 2005.
- Kimball A, Matts PJ. Characterizing Hyper-pigmented Facial Lesions Using Clinical Evaluation and a New Chromophore-Mapping Technique. American Academy of Dermatology 64<sup>th</sup> Annual Meeting, 2006.